

“The People of the Abbey” Skeletal analysis of inhumations from the 2022 and 2023 field seasons.

Ceri Falys, University of Reading

1. Introduction

During the excavations at Cookham Abbey (field-seasons COP22 and COP23), a total of 23 articulated skeletons were recovered from two distinct areas within Trench 2. For ease of description in this report, these locations are designated as inhumations from the “eastern end of Trench 2” and the “western end of Trench 2”. Although all individuals were interred in west (head) to east (feet) alignments, and were all in supine and extended body positions, a possible difference in burial practice between these two areas was evident. In total, 14 individuals were recovered from the 12 earth-cut graves at the eastern side of the trench. There were two double graves, one containing SK2168 and SK2213, and the other SK2170 and SK2171 interred together in graves (2109/2140 and 2079, respectively).

At the western end of Trench 2, a 1.5m wide, north-south sondage was excavated to investigate quantities of disarticulated human and animal bone. Beneath layers of redeposited cemetery soils, a row of densely packed human skeletons, aligned west to east, was identified. An absence of grave cuts was noted at the time of excavation, and the pattern of some of the disarticulated human bone suggests their deliberate positioning within the area, rather than a random spread secondary to burial disturbance. It is possible that several western burials were interred within a short period of time, in an open area rather than individual graves, as was found towards the east side of Trench 2. As a result of the difference in burial rite, individuals from the east and west ends are discussed separately in this report in order to allow for comparison of demography and prevalence of pathological conditions to be made between the two groups.

This report details the initial results for these individuals, providing information on the preservation of the remains, minimum number of individuals within each burial, their biological sex, age-at-death, and skeletal and dental pathology by burial location. The preliminary analysis highlights several avenues for future research that will enable a better understanding of the lives and deaths of the people of Cookham Abbey, and their place in early medieval England.

2. Osteological Analysis

Osteological analysis was undertaken following guidelines by Buikstra and Ubelaker (1994), and BABAO and CIfA (Brickley and McKinley 2004, Mitchell and Brickley 2017). A summary of the findings and additional photographs for each individual can be found in Tables 1 and 9, and the Skeleton Catalogue (Appendix 4).

2.1 Methods

2.1.1 Surface preservation and completeness

Skeletal preservation depends on several factors, both intrinsic and extrinsic to the skeleton itself. Intrinsic factors such as age, biological sex, and the overall size, shape and robusticity of the bone affect the degree of preservation. Extrinsic factors in the burial environment, post-depositional disturbance and post-excavation treatment can also affect the condition of bone. During analysis, preservation was assessed in two ways. First, using a generalized grading system of three categories: poor, fair and good. The definitions are as follows:

- **Poor:** all bone is highly fragmented and demonstrates an eroded and/or damaged cortical bone surface(s). Most elements of the skeleton are not present and/or display severe damage. Trabecular bone has largely not survived, making most osteological analyses impossible.
- **Fair:** cortical bone is somewhat eroded, as well as trabecular bone, making pathological examination not always possible for aspects of the spine, pelvis, and/or joint surfaces of the long bones. A moderate degree of fragmentation is present, most commonly within the axial skeleton (i.e., skull, spine, pelvis, ribs).
- **Good:** cortical bone has little or no damage with large areas of well-preserved bone, sufficiently preserved for osteological and palaeopathological analyses. Trabecular bone has been preserved (i.e., joint surfaces intact, and ribs, vertebrae and pelvis are well represented). A moderate to low degree of fragmentation may be present.

Secondly, the state of preservation of the cortical bone surfaces were assessed following criteria by McKinley (2004, 16), which provides scores ranging between 0 (excellent) to 5+ (poor) to describe the postmortem modification of the outermost surface of cortical bone.

Lastly, the degree of completeness of each individual was made based on estimations of the percentage of expected number of skeletal elements present for analysis, and allocated to the broad categories of <25%, 25%-50%, 50%-75% and 75%.

2.1.2 Biological sex and age-at-death

To maximise the accuracy of osteological assessments, it is necessary to assess as many different skeletal regions as possible to understand trait variation both within and between individuals. The assessment of age-at-death in non-adults relies on the extent of skeletal maturation and dental development, and this was carried out according to Cunningham et al. (2016) and AlQahtani (2010), respectively. Each child was then assigned to one of seven broader age categories to permit comparison of individuals: perinate (i.e., died at or around the time of birth), 0-1 year, 1.1-

2.5 years, 2.6-6.5 years, 6.6-10.5 years, 10.6-14.5 years, and 14.6-17.9 years. Prior to puberty, the macroscopic assessment of biological sex from the skeleton is challenging, however, wherever possible, aspects of the mandible (lower jaw) and ilium (hip blade) were recorded, after Weaver (1980) and Schutkowski (1987), as validated by Sutter (2003).

Once the skeleton and dentition are fully developed, standardized osteological methods for biological sex and adult age-at-death estimation rely heavily on the morphology of the skull and pelvis following Buikstra and Ubelaker (1994), and the distal humerus (Rogers, 1999; Falys et al. 2005). In addition, metrical analysis of the maximum diameters of the right humeral and left femoral heads was also undertaken following criteria by Stewart (1979), to permit comparison with the morphological expressions of biological sex.

An estimation of the age-at-death for adults was made based on dental wear (Brothwell, 1981), and degeneration of the auricular surface of the ilium (Lovejoy et al., 1985) and the pubic symphysis (Brooks and Suchey 1990) in the pelvis. Degeneration of the sternal end of the clavicle was also assessed for individuals in the older age categories (Falys and Prangle, 2015). Each individual was then assigned to one of four broad age categories that account for interpersonal variation in the ageing process: 18-25 years, 26-35 years, 36-45 years, 46+ years (Falys and Lewis 2011).

2.1.3 Stature estimation

As 10% of attained adult stature is reliant on an adequate nutrition and freedom from infection during growth and development, the standing height of an individual can provide information on the environmental circumstances in which they grew up. These data can then be compared to means for males and females from other sites. Stature was estimated using the maximum length (cm) of intact long bones (preferably the femur) using regression equations provided by Trotter (1970).

2.1.4 Non-metric traits

Non-metric or epigenetic traits are variants in the morphology of the dentition and skeleton as the result of genetic or adaptational factors (Tyrell, 2000). They are recognised as additional creases or cusps in the teeth, extra projections of bone, foramina, sutures, facets or canals. These were classified according to Berry and Berry (1967) and Finnegan (1978), and illustrated by Brothwell (1981). Information on non-metric traits is not included here, but is available on request.

3. Results

3.1 Burials from the eastern side of Trench 2

In total, 14 partial or complete individuals were excavated from within 12 single earth-cut graves in this area during the 2022 (COP22 n=1) and 2023 (COP23 n=13) field seasons. Small quantities of disarticulated human bone were collected from the grave fills. However, in graves 2097 (SK2170/2171) and 2127 (SK2182) (Figure 1), larger amounts of disarticulated skeletal remains were present, presumably representing disturbed earlier burials. Two different patterns of reburial were observed, including purposeful placement of the disarticulated remains, and the careless moving out-of-the-way of unwanted bones to the sides of the new inhumation. For example, a neat bundle of long bones was found at the west-end of grave 2097, in the soil layer just above the cranium of SK2171 (possibly the truncated legs of SK2171). In contrast, a large quantity of disarticulated bone appeared to have been pushed to the sides and base of grave 2127 during the internment of SK2182.



Figure 1: Disturbed and disarticulated human bone in graves 2097 (SK2170/2171, left) and 2127 (SK2182, right)

3.1.2 Preservation and completeness

The preservation of the majority of individuals in this area were classified as ‘good’, with greater than 75% of the skeleton available for analysis (n=12, 85.7%). Skeleton 2170 was graded as ‘fair’ (50-75% complete) due to poor preservation of the axial skeleton probably as the result of SK2171 being placed directly above the body, and SK2171 was the least well preserved (‘poor’ or 25-50% complete) as the legs had been truncated by the later burial of SK2172.

Eight individuals (57.1%) had Grade 1, while five (35.7%) displayed patches of more severe surface erosion (Grade 2). SK2171 suffered heavy surface erosion, which masked many of the normal cortical bone surface features (Grade 5).

3.1.3 Biological sex and age-at-death

Assessments of biological sex and age-at-death of the individuals from the eastern area are summarised in Figure 2. The sample comprised seven males (50.0%), six females (42.9%) and one child (SK2168) for whom a biological sex could not be determined (Figure 2).

SK2168 was the youngest individual from this area with a dental age of 12-15 years, and a skeletal age of less than 12 years (age category = 10.6-14.5 years). The fact they were smaller than expected for their age suggest they suffered a degree of stress during their development. The majority of the individuals (n=8, 57.1%) died in later life at over 46 years, with an equal number of males and females.

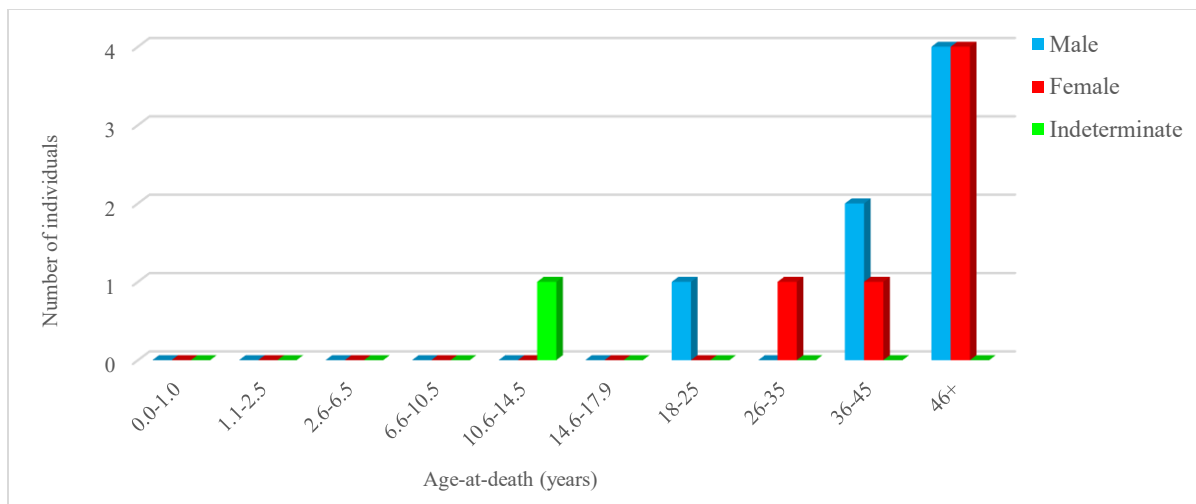


Figure 2: Distribution of biological sex and age-at-death within the eastern area

3.1.4 Stature

Stature was calculated for five of the six females who ranged in height between 150cm and 161cm (or 4'11" to 5'3"), with an average of 154cm or 5 feet (Figure 3). For males, data was available for seven individuals with a range of 160cm to 182cm (or 5'3" to 5'11") and an average of 175cm (5'8"). Roberts and Cox (2003, 195) found a taller average stature for females in the early medieval period of 161cm or 5'3" (152cm-170cm) and a smaller average for males of 172cm (5'7", with a range of 170cm-182cm). The osteological data for the eastern area burials is summarised in Table 1.

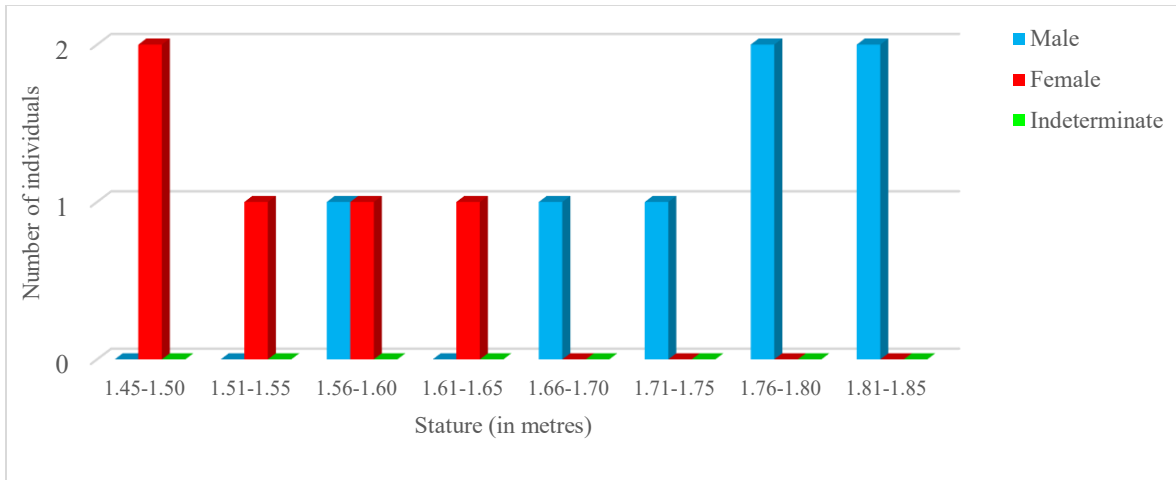


Figure 3: Estimated stature (in metres) for males and females in the eastern area.

Table 1. Demography and stature of the eastern burials from Trench 2

Skeleton	%Complete (surface)	Biological sex	Age (years)	Stature	
				cm	Ft in
2160	75+ (2)	Male	36-45	169.0cm ± 3.27cm (left femur)	5'7"
2161	75+ (1)	Male	46+	178.7cm ± 3.27cm (right femur)	5'10"
2168	75+ (1)	Male?	10.6-14.5	-	-
2169	75+ (2)	Male	17-25	181.4cm ± 3.27cm (right femur)	5'11"
2170	50-75 (5)	Female	46+	-	-
2171	25-50 (1)	Male	46+	177.9cm ± 4.05cm (right humerus)	5'10"
2172	75+ (1)	Female?	26-35	161.1cm ± 3.72cm (left femur)	5'3"
2173	75+ (1)	Male	36-45	173.5cm ± 3.27cm (left femur)	5'8"
2175	75+ (2)	Female	36-45	156.4cm ± 3.72cm (right femur)	5'1"
2181	75+ (1)	Male	46+	160.2cm ± 3.27cm (right femur)	5'3"
2182	75+ (2)	Female	46+	150.4cm ± 3.72cm (right femur)	4'11"
2210	75+ (1)	Female	46+	150.7cm ± 3.72cm (left femur)	4'11"
2213	75+ (2)	Male	46+	182.3cm ± 3.27cm (left femur)	6'0"
2226	75+ (1)	Female	46+	152.9cm ± 3.72cm (right femur)	5'0"

3.1.5 Health status

Skeletal pathology can provide information on living conditions, diet, occupation, access to medical care, as well as numerous other aspects of everyday life of past populations (Roberts 2009). Pathological changes observed for the eastern burials were classified into broad categories of pathology: dental disease (e.g., caries, calculus,

abscesses, periodontal disease, antemortem tooth loss, linear enamel hypoplasia, and other dental anomalies), antemortem trauma (i.e., healed or healing injuries), congenital and developmental anomalies (e.g., spina bifida occulta, lumbarisation, spondylosis, abnormal vertebral development and os acromiale), degenerative joint disease (including osteoarthritis and Schmorl's nodes). The less frequently occurring pathologies were infectious disease (i.e., specific and non-specific infection), circulatory disruptions (e.g., osteochondritis dissecans), evidence of perimortem trauma (i.e., trauma occurring at or around the time of death), and neoplastic diseases. A summary of the pathological conditions of each individual is provided in Appendix 1, and comparisons with other early medieval sites across Britain found in Appendix 3.

3.1.5.1 Dental health

Teeth can provide information on more than just oral hygiene. Dental disease reflects the quality of the diet and the enamel on tooth crowns can record periods of illness or malnutrition during childhood. Dentition was recovered from all 14 eastern burials, with a total of 297 adult (permanent) teeth present for analysis (136 maxillary, 161 mandibular). No deciduous teeth were present. Overall, the dentition was well preserved, which permitted investigations of the prevalence of antemortem tooth loss, caries (cavities), calculus (plaque deposits), periapical lesions (e.g., abscesses), alveolar resorption (gingivitis), and enamel hypoplasia. Crude (CPR) and true prevalence rates (TPR) of dental disease are provided where possible, and a summary of observed dental disease is provided in Appendix 2.

3.1.5.1.1 Antemortem Tooth Loss (AMTL)

The loss of teeth before death can result from many reasons, including severe dental attrition, caries, periodontal disease, abscesses, advancing age, and are characterized by healing of the tooth socket. In total, five individuals (CPR= 35.7%; SK2172 (?F), SK2181 (M), SK2182 (F), SK2210 (F), and SK2226 (F)), all aged 46+ years, lost teeth a significant amount of time prior to death. Between 1 (SK2172) and 24 (SK2210) were lost. Of the 391 sockets present for analysis, 53 displayed antemortem tooth loss (TPR=13.6%). Roberts and Cox (2003, 190-194) found the rate to be 8.0%.

3.1.5.1.2 Carious Lesions

Caries are progressive diseases during which bacteria contribute to the erosion and destruction of tooth crowns and/or roots, commonly associated by acids that develop from the bacterial fermentation of food sugars (e.g., sucrose). A total of seven individuals (CPR = 7/13; 53.9%; SK2160 (M, 36-45 years), SK2161 (M, 46+ years), 2170 (F, 46+ years), 2171 (M, 46+ years), SK2172 (?F, 26-35 years), SK2181 (M, 46+ years), and SK2226 (F, 46+ years)) displayed between one (SK2170 and SK2172) and three (SK2161 and SK2181) carious lesions (TPR = 14 caries/297 teeth present = 4.7%). Roberts and Cox (2003, 190-191) found the rate to be 4.2%.

3.1.5.1.3 Calculus

Calculus is the mineralization of dental plaque that collects on the surfaces of the tooth crowns. Daily brushing of teeth removes plaque before it can calcify, so the presence of calculus indicates that dental hygiene was not a daily priority. Archaeologically, calculus deposits are most commonly identified on the buccal (cheek) and lingual (tongue) surfaces of the dentition. Occasionally calculus deposits can be present on the occlusal surfaces of teeth (i.e., the biting surfaces), either unilaterally (one sided), or bilaterally, which would indicate the individuals was not actively chewing food (or other materials) on the affected side(s) of the mouth.

Deposits of calculus were observed on the dentition of all 13 of the 13 individuals buried in the eastern side of trench 2 with dentition present for analysis (i.e., SK2182 was not included in the analysis due to absence of all tooth crowns; CPR = 100.0%). The severity of calculus deposits was scored following Brothwell (1981): “slight”, “medium” and “considerable”. In total, 11 individuals displayed “slight” deposits, one had “medium” (SK2226, F, 46+ years), and one had “considerable” (SK2168, 10.6-14.5 years-old), with the right side of the mouth primarily affected (Figure 4). In the absence of evidence of an abscess or other lesion which may have caused pain during chewing, the considerable build-up of calculus suggests the child had paralysis of the right side of their mouth. Roberts and Cox (2003, 190-194) found the rate to be 39.2%.

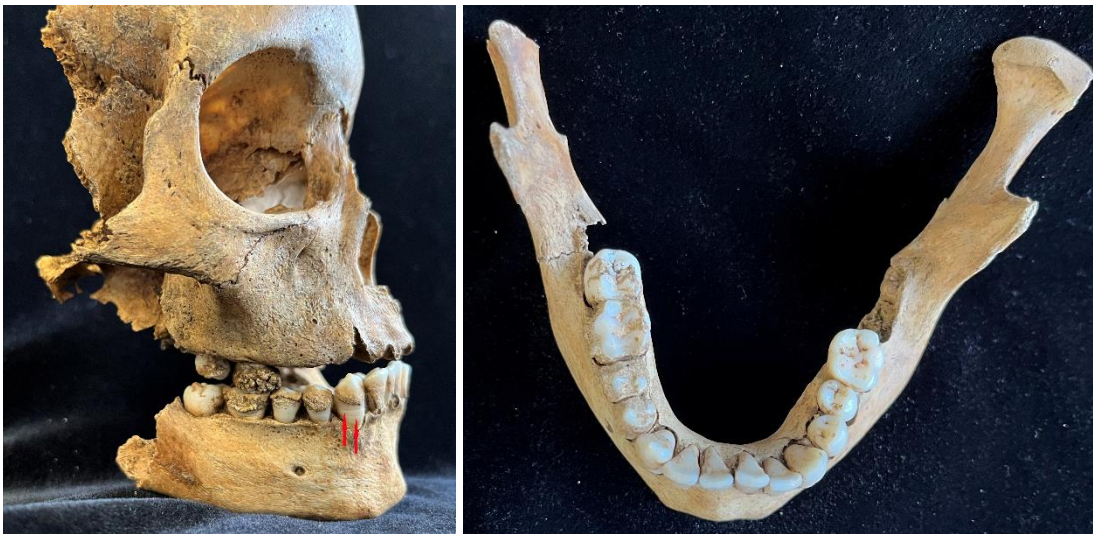

Figure 4: “Considerable” calculus on the buccal surface of the right maxillary and mandibular dentition (left), also note lines of enamel hypoplasia (arrowed); Right: occlusal calculus on the right mandibular dentition.

Of the 13 individuals with calculus, five also displayed calculus deposits on the occlusal surfaces of the dentition, indicating food was not being actively chewed, which could be the result of either pain or paralysis. SK2168 (10.6-14.5 years), SK2170 (F, 46+ years), SK2171 (M, 46+ years), SK2181 (M, 46+ years) and SK2213 (M, 46+ years) (CPR = 5/13 individuals = 38.5%), with deposits most commonly visible on the wear facets of the molars.

3.1.5.1.4 Periapical lesions

Periapical lesions (abscesses, granulomas, cysts) result from bacteria entering the roots or pulp cavities of teeth. Caries, trauma, and severe wear all provide the openings in dental enamel that give rise to abscesses. The symptoms are pus and pain, and produce characteristic hole(s) in the surrounding jaw where the pus can exude through the bone. A total of four individuals had well-defined holes observed in their jaws (CPR = 4/14 = 28.6%; SK2161 (M, 46+ years), SK2171 (M, 46+ years), SK2172 (?F, 46+ years) and SK2210 (F, 46+ years)). Roberts and Cox (2003, 190-194) found the rate of periapical abscesses to be 2.7%.

3.1.5.1.5 Periodontal Disease

Commonly known as gingivitis or gum disease, periodontal disease is the chronic inflammation of the soft tissue of the gums. Ultimately, the chronic inflammation gradually resorptions the alveolar bone of the maxilla and/or mandible. As the alveolar bone recedes, antemortem tooth loss can result, as the roots of the dentition become less and less anchored in the bone. During analysis, the degree of resorption of the alveolar bone was graded following Brothwell (1981): “slight”, “medium” and “considerable”. Of the individuals with suitably preserved maxillary and/or mandibular alveolar processes (n=13, excluding SK2170), 10 individuals displayed some degree of alveolar resorption (CPR = 76.9%). Perhaps related to younger ages-at-death, SK2160 (M 36-45 years), SK2168 (10.6-14.5 years) and SK2169 (M, 17-25 year) did not display observable receding of the alveolar bone. In contrast, five individuals displayed “slight” resorption (SK2172 (?F, 26-35 years), SK2173 (M, 36-45 years), SK2175 (F, 36-45 years), SK2181 (M, 46+ years), and SK2213 (M, 46+ years)), three displayed “medium” (SK2161 (M, 46+ years), SK2171 (M, 46+ years), and SK2226 (F, 46+ years)), and two displayed “considerable” (SK2182 (F, 46+ years) and SK2210 (F, 46+ years)). It is noted the latter two individuals provided evidence for the most amount of antemortem tooth loss in the eastern burials.

3.1.5.1.6 Enamel Hypoplasia

Enamel hypoplasia are linear defects of the enamel that are formed in response to nutritional deficiency and/or pathological events (e.g., acute illness, high fever) during childhood. While the crowns are developing within the jaws (commonly under the age of 7 years), these episodes of disease or malnutrition cause a cessation of growth in order to re-direct the body’s energy into healing the physiological stress, resulting in deficiencies of the enamel (see defects on mandibular canine in Figure 4). These defects can take the form of grooves or pits, broad bands of hypomineralization or honeycombed beds of cup-shaped enamel voids (Langsjoen 1998). Excluding SK2182, for whom no teeth were recovered, clear horizontal linear defects were recorded on the anterior dentition (i.e., incisors, canines, and/or premolars) of seven eastern burials (CPR = 7/13 = 53.8%; SK2160, SK2161, SK2168, SK2169, SK2173, SK2175 and SK2226), signifying they survived period(s) of illness/systemic stress during childhood.

3.1.5.2 Congenital and developmental anomalies

The most commonly identified congenital and developmental anomalies are found in the vertebral column (Barnes 1994). Such conditions can result from genetic factors, such as poor maternal health (e.g., virus infection, poor diet), environmental pollution or trauma in the womb. Congenital conditions that severely affect the growth and/or development of the baby would have resulted in the death of the individual before or at birth, making them invisible in the archaeological record (Roberts and Manchester 1995). Of the 14 eastern burials, seven (50.0%) individuals displayed congenital/developmental anomalies, with the majority (n=4 individuals) displaying more than one.

3.1.5.2.1 Spina Bifida Occulta

The most frequent congenital/developmental condition in the eastern burials was spina bifida occulta, which is characterized by the incomplete development of one or more of the neural arches of the sacrum, although other vertebrae can also be affected. The non-fusion of the sacral neural arch(es) results in the sacral canal remaining open, and thus not adequately enclosing the spinal cord (Ortner 2003), leaving it more susceptible to damage. This condition is linked to the lack of folic acid during pregnancy (i.e., suggests multigenerational health problems – dietary deficiency in the mother), and is asymptomatic in the majority of cases, however, in the most severe expressions, this condition may produce paralysis in one of more limbs. For this analysis, non-fusion of the fourth (S4) and fifth (S5) sacral neural arches were considered to be normal variation between individuals, and not classified as spina bifida (Barnes, 1994). In total, five of the Eastern burials with sacra (5/13, 38.5%, excludes SK2170) displayed non-fusion of sacral neural arches of varying patterns (not including non-fusion of S4 and/or S5). SK2173 (M, 36-45 years) had complete non-fusion of all sacral neural arches (Figure 5), SK2169 (M, 17-25 years) and SK2181 (M, 46+ years) had non-fusion of the first sacral vertebral neural arch as well as lower ones, and SK2168 (10.6-14.5 years) and SK2133 (M, 46+ years) had non-fusion of at least the third neural arch (damage present to upper sacral neural arches).

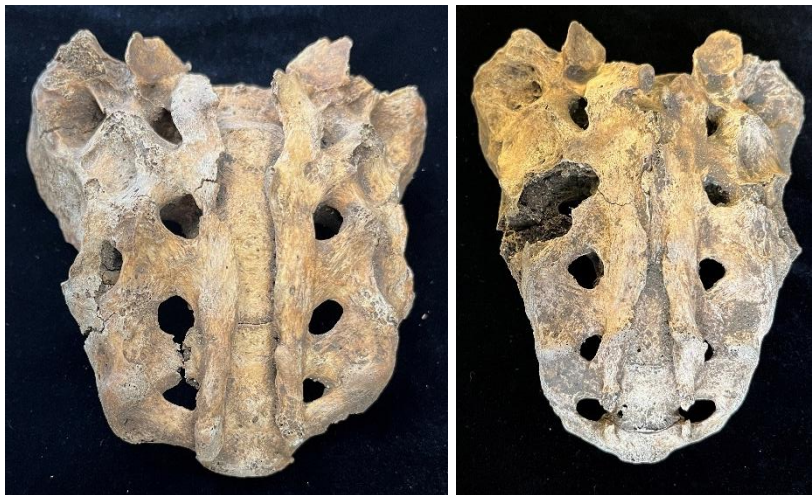

Figure 5: non-fusion of sacral neural arches (spina bifida occulta), complete non-fusion of S1-S5 of SK2173 (left), and S1, S3-S5 of SK2169 (right).

3.1.5.2.2 *Border-shift Vertebrae*

Congenital and developmental abnormalities can cause border-shifts of vertebrae (e.g., lumbarisation of sacral vertebrae and/or sacralisation of lumbar vertebrae), or cause the formation of additional vertebrae (i.e., supernumerary vertebrae). Although the bones of the spine were not always suitably preserved for analysis, a minimum of four eastern burials (4/12 individuals or 33.3%) do not match the normal vertebral pattern, with lumbarisation of the twelfth thoracic vertebra (i.e., the twelfth thoracic vertebra displayed superior articular facets of a lumbar vertebra, while retaining the costal facets). Such border-shift abnormalities are unlikely to have caused symptoms in life (Aufderheide and Rodriguez-Martin 1998).

3.1.5.2.3 *Spondylolysis*

Spondylolysis is a defect of the vertebral neural arches that results in either the non-union of the arch to the vertebral body, or its later detachment, possibly the result of a repetitive stress (e.g., bending and lifting) applied to a hereditary weakness rather than an acute traumatic event (Ortner 2003). Spondylolysis most commonly affects the fourth and fifth lumbar vertebrae and a symptom of this condition is lower back pain. One case of this was present within the eastern burials (1/12 or 8.3%), which was observed in the fifth lumbar vertebra of SK2226 (F, 46+ years).

3.1.5.2.4 *Abnormal fusion of Neural Arches of the Thoracic Vertebrae*

Of the spinal congenital and/or developmental defects observed in the eastern burials, the most unusual was identified on the neural arches of the fourth through the eleventh thoracic vertebrae of SK2171 (M, 46+ years). Although the preservation of the vertebrae was less-than-ideal (i.e., the bodies and neural arches were not well preserved), the dorsal aspects of the neural arches display abnormal “double” appearances (i.e., a transverse groove midway down the neural arch (Figure 6), suggesting the incomplete segmentation of the spine during skeletal development, although the condition did not result in the ankylosis of adjacent vertebrae (i.e., one pair of pedicles per neural arch). Further research is needed to investigate the cause and physical effect(s) of such an abnormality.

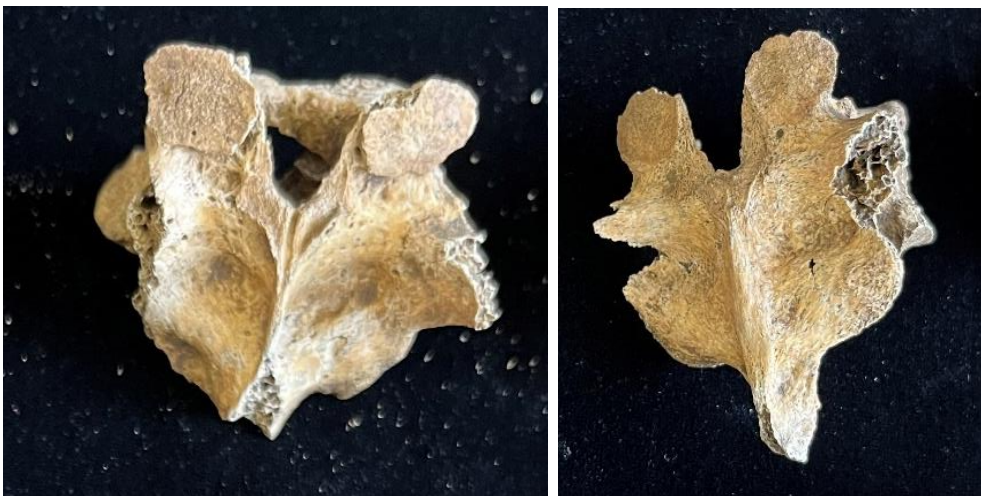

Figure 6: segmentation anomaly of the thoracic vertebrae of SK2171

3.1.5.2.5 *Os acromiale*

One extra-spinal congenital /developmental defect was observed in SK2173 (M, 36-45 years), in the form of abnormally developed scapulae (shoulder blades). The tips of the acromion processes were fully developed, but were unfused from the acromia/scapular spine, an event that usually occurs between the ages of 18-20 years (Cunningham et al. 2016). This condition is known as *os acromiale*, and suggests strenuous activities were undertaken by the shoulders (rotator cuff muscles) during adolescence when the individual was still growing and skeletally maturing.

3.1.5.3 Trauma

Skeletal trauma can occur accidentally or intentionally, as the result from cultural practices or therapeutic/surgical intervention (Cuhna and Pinheiro 2009). Traumatic wounds (for example, fractures, trepanations, weapon trauma, dislocations, haematomas, etc) may result in the damage of soft tissue and/or bone. Trauma is broken down further into the categories antemortem and perimortem, the differentiation between the two depending on the timing of the injury. Antemortem wounds are inflicted a sufficient amount of time before the death for healing to commence (i.e., active bone remodelling, rounded wound margins, inflammation, infection, or well-healed lesions). While antemortem injuries indicate the victim survived for some time following the injury, perimortem wounds are inflicted at or very close to the time of death. These injuries are characterized by sharp and irregular margins, completely devoid of healing. Both types of traumas were observed in the eastern burials, as described below.

3.1.5.3.1 Antemortem trauma

A total of nine individuals (64%) of individuals from the eastern end of Trench 2 had evidence of skeletal trauma. In some cases a radiograph will be needed to confirm the diagnosis and extent of healing (Table 2). Four individuals had fractures that were in the process of healing, including SK2160, a male aged 36-45, with a healing fracture of the right distal fibula and two older females with healing fractures to ribs. While these were probably the result of accidental (or interpersonal) traumatic events, one male (SK2171) had healing circular trepanation (trephination) to the top of the head indicative that he underwent surgery shortly before his death (Figure 7).

Table 2: Summary of antemortem trauma in Eastern burials. * need further investigation to confirm

Skeleton number	Biological sex	Age (years)	Bone(s) affected		Status of healing
			Side	Location	
2160	Male	36-45	Right	Distal fibula	Healing (callus present)
2169*	Male	17-25	Indeterminate side	Proximal manual phalanx of first finger (thumb)	Healing
			Right	Distal radius	Healed (?) X-ray needed to confirm diagnosis

Skeleton number	Biological sex	Age (years)	Bone(s) affected		Status of healing
			Side	Location	
			Indeterminate side	Intermediate and distal pedal phalanges	Fused elements (ankylosis)
2171	Male	46+	Midline	Parietals	Trepanation (healing)
			Left	Rib shafts (at least 3)	Healed
2172*	Female?	26-35	Right	Cranium (frontal – oblong nodule), anterior femur (ridge)	Healed
2173	Male	36-45	Indeterminate side	Proximal pedal phalanx	Healed
2181	Male	46+	Left	T5	Healed
			Right	T11	Healed
			Anterior	L3	Healed
			Right	Clavicle (sternal end)	Healed
			Right	Ulna (distal)	Healed-ray needed to confirm diagnosis
2182	Female	46+	Indeterminate side	Ribs	Healing (callus formation)
2210	Female	46+	Right	T7-T9	Healed
			Indeterminate side	Rib shafts	Healing
2226	Female	46+	Left	Scapula (blade)	Healed
			Ventral	S3-S4 bodies	Healed

The trepanation penetrated the inner table of the cranium and was located half way along the sagittal suture (Figure 7), and appears to be of the drilled type. As a drill (a trephine) was used to create the small hole (approx. 1.3cm diameter), the lesion is most accurately called a trephination (Roberts and Manchester, 2012, 126). The ectocranial surface of the lesion has a bevelled edge, which slopes down to the main, centrally located site of perforation. The wound shows evidence of healing, in the form of porosity and smoothing of the edges. This lesion is remarkable due to the fact that the man survived for a period of time after the surgery that allowed the wound to begin the healing process. Directly beneath the drilled location, a major blood vessel (the sagittal sinus) runs. If punctured, certain death would occur. The trephined area is surrounded by diffuse new bone formation on the endocranial surface. It is not known whether the surgery was performed to help alleviate the symptoms of this intracranial infection (perhaps the result of a haemorrhage), or whether the traumatic wound resulted in the bone reaction. There is no evidence of underlying trauma to the skull.



Figure 7: Healing antemortem trepanation to the top of the head of SK2171: ectocranial surface (left), endocranial surface with diffuse periosteal reaction (right).

3.1.5.3.2. *Perimortem trauma*

One older male (SK2161) displayed extensive perimortem wounds to the left side of his body, and the right side of his head. The wounds show no evidence of healing, and have likely led to the death of SK2161. A large, rectangular-shaped penetrating wound (blunt force trauma) is located on the mid right parietal bone. The force of the wound fractured the cranial vault, and pushed fragments into the brain case (Figure 8). The posterior aspect of the right parietal bone and occipital bone also display two puncture wounds, although, perhaps due to the increased thickness of these portions of the cranium, they did not penetrate the thickness of the cranial vault. The wounds are oblong in shape, and were likely caused by a different implement than the rectangular-shaped wound on the right parietal. Neither type of wound appears to have been made by a sharp-edged object.

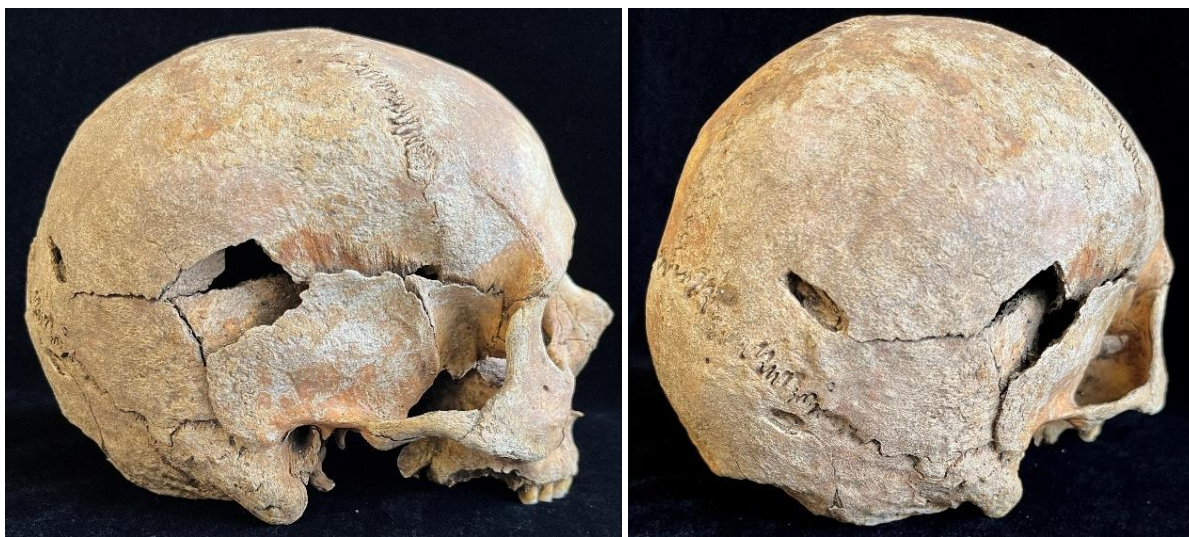

Figure 8: SK2161 cranial trauma to the right parietal bone (left), and right side of the back of the head (right)

Several post-cranial perimortem fractures are also present, including the left side of the mandible (ascending ramus), the left shoulder (scapula, proximal humerus and clavicle), the left radius and ulna, the left and right ilia (hip blades), and right distal fibula shaft (Figure 9). The lesions to the skull likely resulted in internal bleeding that would have damaged the brain leading to death if the bleeding was not controlled. Perimortem injuries can appear to be unhealed for up to 5 days after the trauma (Cuhna and Pinheiro 2009), so it is possible the man was brought to the site a short time after he sustained these injuries.

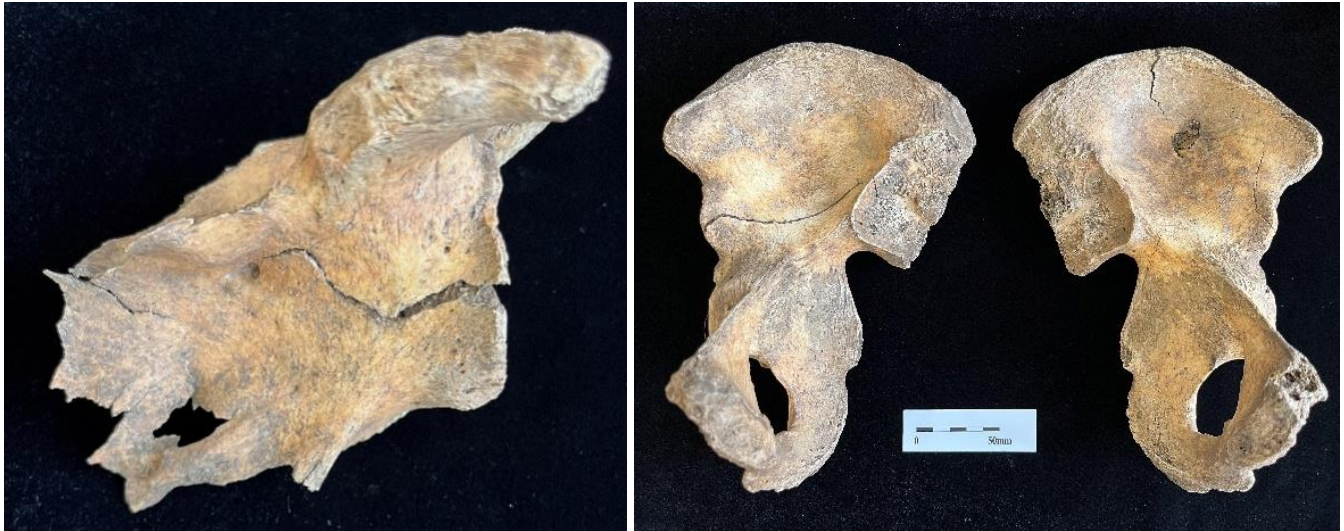

Figure 9: SK2161 post-cranial fractures of the left scapula (left) and ilia (right)

3.1.5.4 Degenerative joint disease

Osteoarthritis is a form of degenerative joint disease that only affects the synovial joints (Roberts and Manchester 1995). It most commonly affects the weight-bearing joints of the body, although any synovial joint can be affected. Its presence signifies that biomechanical wear and tear have been placed on the joints of the skeleton, which commonly accumulate over a life time (i.e., linked to advancing age). Symptoms, depending on degree of arthritis, can be impairment of movement and/or pain. Osteoarthritis manifests itself in three ways: osteophytes, surface contour change, porosity, and/or eburnation. Waldron and Rogers (1991) suggest that eburnation is the most diagnostic feature of osteoarthritis, and if this is not present, the other three criteria must be evident for a diagnosis of osteoarthritis.

3.1.5.4.1 Spinal Joint Disease

As expected from the high number of older individuals buried towards the east side of Trench 2, degenerative joint disease (DJD) was recorded in 12 of the 13 adult individuals (excluding non-adult SK2168). It is noted that SK2170 (F, 46+ years) was poorly preserved and accurate assessments of DJD was not possible due to fragmentation and surface damage. A summary is provided in Table 3.

Of those individuals, two (SK2169 (M, 17-25 years) and SK2172 (F, 26-35 years) only displayed Schmorl's nodes, not any additional spinal or extra spinal evidence of degenerative joint disease. Unlike other degenerative changes, Schmorl's nodes do not increase in number with age, as they most commonly form during adolescence, usually before the age of 18 years (Resnick and Kransdorf 2005). Visible as pits or depressions of thoracic and lumbar vertebral bodies, Schmorl's nodes are formed by the contents of the vertebral disc exerting pressure on the vertebral body surface (Roberts and Manchester 2012). They are often asymptomatic, and their aetiology is complex, although spinal trauma caused by vigorous activity and flexion and extension of the spine are most commonly associated with their formation (Kyeret et al. 2012). In total, the vertebral bodies of eight individuals displayed shallow depressions, characteristic of Schmorl's nodes (CPR = 8/13, 61.5%), with males affected more than females (CPR males = 6/7, 85.7%, females 2/6, 33.3%). Roberts and Cox (2003, 198) found the CPR of Schmorl's nodes in the early medieval period to be to be 24.7%.

Of those with spinal DJD (i.e., osteophyte formation and/or porosity of joint surfaces) (CPR = 10/13, 76.9%), most commonly observed as marginal lipping of the vertebral bodies in the spine (CPR=8 individuals, 61.5%; males 5/7, 71.4%, females 3/6, 50.0%) (SK2160 (M, 36-45 years), SK2161 (M, 46+ years), SK2173 (M, 36-45 years), SK2175 (F, 36-45 years), SK2181 (M, 46+ years), SK2182 (F, 46+ years), SK2210 (F, 46+ years), SK2213 (F, 46+ years), SK2226 (F, 46+ years)).

Table 3: Crude prevalence rate of degenerative joint disease in the adult eastern area burials (n=13)

Joint affected	Males (n=7)			Females (n=6)		
	n	Affected	CPR (%)	n	Affected	CPR (%)
TMJ	7	1	14.3	6	2	33.3
Spine	7	5	71.4	6	3	50.0
Schmorl's nodes	7	6	85.7	6	2	33.3
Right shoulder	6	1	16.7	6	2	33.3
Left shoulder	7	1	14.3	6	2	33.3
Right elbow	6	-	-	6	-	-
Left elbow	7	-	-	6	-	-
Right wrist/hand	6	1	16.7	6	-	-
Left wrist/hand	6	-	-	6	-	-
Right hip	7	1	14.3	6	2	33.3
Left hip	7	1	14.3	6	2	33.3
Right knee	6	-	-	6	-	-
Left knee	6	-	-	6	-	-
Right ankle/foot	5	-	-	6	-	-
Left ankle/foot	5	-	-	6	-	-

3.1.5.4.2 Osteoarthritis

Three older individuals (28.6%) had developed osteoarthritis of joints (i.e., eburnation) (Table 4), including the left elbow of SK2226 (46+, F), the facets of the cervical vertebrae, right shoulder and hip joints of SK2170 (F, 46+ years), the left inferior sternal clavicle of SK2210 (F, 46+ years) and the left hip of SK2171 (M, 46+ years).

Table 4: Crude prevalence rate of degenerative joint disease in the adult eastern area burials (n=13)

Joint affected	Males (n=7)			Females (n=6)		
	n	Affected	CPR (%)	n	Affected	CPR (%)
TMJ	7	-	-	6	-	-
Spine	7	-	-	6	1	16.7
Right shoulder	6	-	-	6	1	16.7
Left shoulder	7	-	-	6	1	16.7
Right elbow	6	-	-	6	-	-
Left elbow	7	-	-	6	1	16.7
Right wrist/hand	6	-	-	6	-	-
Left wrist/hand	6	-	-	6	-	-
Right hip	7	-	-	6	1	16.7
Left hip	7	1	14.3	6	1	16.7
Right knee	6	-	-	6	-	-
Left knee	6	-	-	6	-	-
Right ankle/foot	5	-	-	6	-	-
Left ankle/foot	5	-	-	6	-	-

3.1.5.5 Infections

In palaeopathology, infectious diseases fall into two categories, non-specific infections, where the pathogen is unknown, and those with a specific cause (e.g., leprosy, syphilis, tuberculosis). Non-specific infections result from unknown pathogens, and can manifest in the inflammation of three different aspects of a bone: sub-periosteal new bone formation affects the fibrous sheath (periosteum) that covers the outermost layer of a skeletal element, osteitis is the inflammation of the cortical bone (the thick, dense external layer of bone), and osteomyelitis, which results from infection deep within the medullary cavity.

3.1.5.5.1 Sub-periosteal new bone formation (SPNB).

Identified as plaques of porous, grey or light brown woven (or fibre) bone on the surface of the cortical bone, sub-periosteal new bone indicates the bone was actively remodelling at the time the individual died. As the remodelling process progresses, the woven appearance of the initial fibre bone takes on a smoother, denser textured bone (lamellar), which indicates the condition was present for some time prior to death, and the body had time to start

the healing process. In total, 10 individuals (CPR = 10/14, 71.4%) buried within the eastern end of Trench 2 displayed periosteal reaction, with all individuals having two or more skeletal regions affected (Table 5).

Endocranial new bone formation was noted in four individuals, including the male with the trephination. This individual also had new bone formation along the nasal aperture, within the maxillary sinuses (sinusitis), and on the ilia, perhaps indicating a more widespread condition that resulted in his treatment.

Table 5: Distribution of active new bone formation in the eastern area burials.

Skeleton number	Biological sex	Age-at-death (years)	Cranium	Chest	Spine	Pelvis	Upper limb		Lower limb	
							Humerus	Forearm/hands	Femur	Lower leg/feet
2160	Male	36-45	-	Ribs (right)	-	Yes	Yes	Yes	Yes	Yes
2161	Male	46+	-	-	-	Yes	-	-	-	Yes
2169	Male	17-25	-	Yes	-	-	-	-	Yes	Yes
2170	Female	46+	Yes	-	-	-	-	-	-	-
2171	Male	46+	Yes	-	-	Yes	-	-	-	-
2172	Female?	26-35	Yes	Ribs (left)	-	-	-	-	-	Yes
2173	Male	36-45	-	-	Yes	-	Yes	-	Yes	Yes
2175	Female	36-45	Yes sinusitis	Yes	-	-	-	-	Yes	Yes
2210	Female	46+	-	-	-	-	-	-	Yes	Yes
2213	Male	46+	-	Yes	-	-	-	-	Yes	Yes

3.1.5.5.2 Specific infection

The only adolescent in the eastern sample (SK2168) had lesions that suggested they had suffered from a chronic condition for some time before they died, likely resulting in them being small for their age. Their skeleton displayed a combination of lytic and blastic lesions, including an erosive lesion on the sphenoid (in the skull), periosteal new bone formation around nasal cavity and the temporo-mandibular joint, accentuated porosity of the vertebral bodies, active new bone formation on the postcranial skeleton and porosity of the palmar and plantar surfaces of the metacarpals, metatarsals and phalanges. It is likely SK2168 suffered from an infectious disease like tuberculosis or brucellosis, a zoonotic disease transferred from infected animals through close-contact or ingesting infected animal products.

3.1.5.6 Indicators of non-specific stress

Cribriform orbitalia is a common palaeopathological condition that has been traditionally linked to iron-deficiency anaemia, either through malnutrition, parasitic infection, or excessive blood loss (Roberts and Manchester 2012).

However, Walker et al. (2009) suggested that it may be the result of megaloblastic anaemia resulting from a deficiency of vitamins B12 and B9. These vitamins are found in animal products such as fish, shell fish, cheese, eggs, lamb, beef, etc. Four individuals (28.6%) from the eastern sample had cribra orbitalia. Roberts and Cox (2003) reported a CPR of 7.6%.

3.1.5.6.1 Limb Asymmetry

Another possible indication of systemic stress is the asymmetry of the long bones. Although limb-length is influenced by genetics, they can also be affected by environmental and biomechanical factors. For example, length and robusticity the humerus and clavicle may suggest, as the dominant arm would be more frequently used for tasks for the overall length and robusticity would be larger than the non-dominant arm. However, environmental stresses, such as malnutrition, excessive noise, cold and heat can also enhance long bone asymmetry. Pathological conditions may be identified if side differences are pronounced. Table 6 and Figure 10 summarise the maximum lengths of the humeri and femora (cm), where suitably preserved, as well as the calculated difference in length between the left and right sides (left (cm) – right (cm) = long bone length difference in cm). Resultant differences with negative results indicate the right side was longer than the left.

Table 6: Maximum length (cm) of the left and right humeri and femora for individuals buried in the eastern graves.

Skeleton number	Biological Sex	Age-at death (years)	Humerus			Femur			Stature
			Left	Right	Diff.	Left	Right	Diff.	
2160	Male	36-45	32.1	31.9	0.2	45.2	44.9	0.3	169.0cm ± 3.27cm
2161	Male	46+	34.3	35.1	-0.8	49.1	49.3	-0.2	178.7cm ± 3.27cm
2169	Male	17-25	-	36.6	-	50.3	50.4	-0.1	181.4cm ± 3.27cm
2171	Male	46+	33.8	34.9	-1.1	-	-	-	177.9cm ± 4.05cm (right) or 174.6cm (left humerus)
2172	Female?	26-35	29.6	30.3	-0.7	43.3	42.7	0.6	161.1cm ± 3.72cm (left) or 159.6cm (right femur)
2173	Male	36-45	33	33.8	-0.8	47.1	46.7	0.4	173.5cm ± 3.27cm (left) or 172.6cm (right femur)
2175	Female	36-45	29.2	29.5	-0.3	41.3	41.4	-0.1	156.4cm ± 3.72cm (right femur)
2181	Male	46+	30.2	30.7	-0.5	41.4	41.5	-0.1	160.2cm ± 3.27cm (right femur)
2182	Female	46+	-	-	-	38.7	39	-0.3	149.7cm ± 3.72cm (left) or 150.4cm (right femur)
2210	Female	46+	28.4	28	0.4	39.1	-	-	150.7cm ± 3.72cm (left femur)
2213	Male	46+	35.4	36.3	-0.9	50.8	-	-	182.3cm ± 3.27cm (left femur)
2226	Female	46+	28.6	28.7	-0.1	40	39.6	0.4	152.9cm ± 3.72cm (right femur)

Asymmetry of the humerus or femur could be assessed for 12 individuals in the sample, with seven individuals having both elements preserved for comparison. In these cases, the humerus displaying greater asymmetry than the femur. The most marked symmetry was found in a 26-35 years old possible female (SK2172), whose right humerus

was 0.7cm longer than their left, and whose left femur was 0.6cm longer than the right. A young male (SK2173) also had a longer right humerus (0.8cm difference), and a shorter right femur (0.4cm difference). Significant differences between the lengths of the leg bones may suggest the individual would have walked with a limp. Also of note, although two individuals lacked preserved femora, three 46+ year old males, SK2161, SK2171, and SK2213 each had significant differences, with the right side 0.8cm-1.1 cm longer than the left (Table 6). Interestingly, these three individuals are among the tallest of the eastern burials.

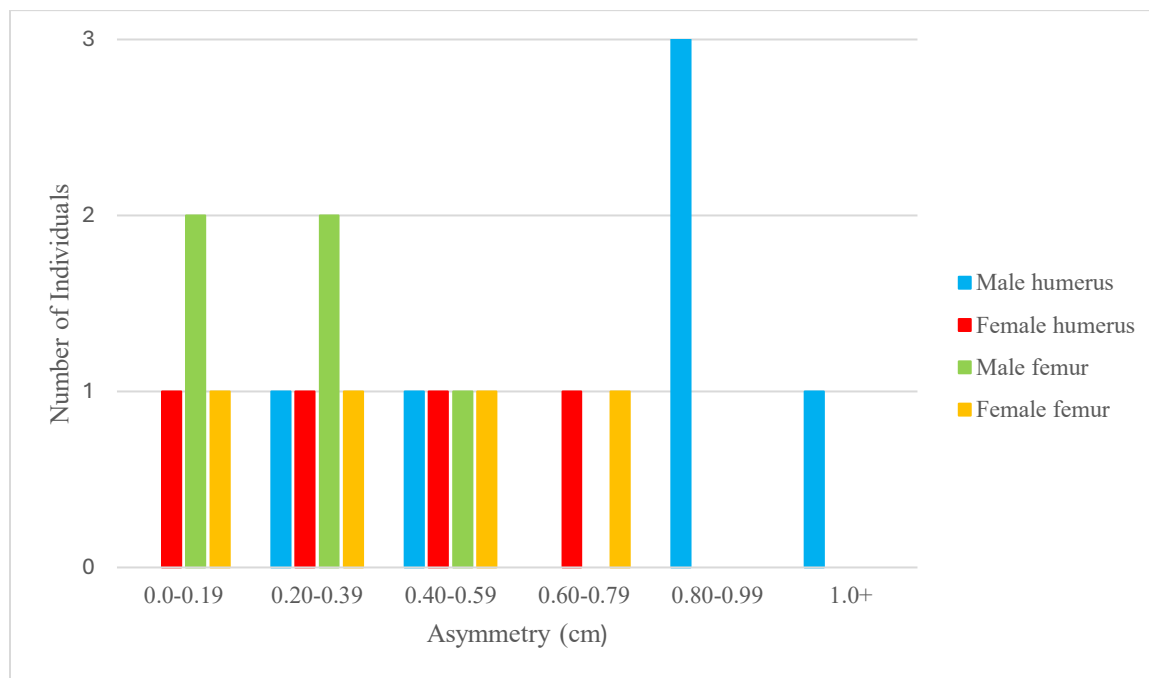


Figure 10: differences (asymmetry) between the maximum length of the left and right humeri and femora, by biological sex.

3.1.5.7 Neoplastic disease

Neoplastic diseases are characterized as new or abnormal growths caused by uncontrolled growth of tissue cells (Roberts and Manchester 1995), although are more commonly known as cancer. Two categories of neoplasm exist: benign and malignant. Benign neoplasms do not tend to spread from their point of origin (Roberts and Manchester 1995), or threaten life. Clinically, they are largely asymptomatic, and do not produce pain. In contrast, malignant cancers are characterized by uncontrolled growth and/or spread throughout the body via the blood stream, lymphatic system, or direct implantation of cells in organ tissues (Roberts and Manchester 1995). Metastases (secondary deposits) manifest themselves in organs, disrupting and breaking down the normal function, and resulting in death. Clinically, malignant cancers produce symptoms including weight loss, anaemia, and pain.

No benign neoplasms were observed in the eastern burials, however, a minimum of two cases of metastatic neoplastic disease have been identified. It is noted that much more research in the form of a radiographic survey is needed to fully investigate the prevalence of cancer at the site.

3.1.5.7.1. Skeleton 2181 (Male, 46+ years)

A possible neoplastic condition was identified on within the pelvis of SK2181 (M, 46+ years). A large, space-occupying lesion is located on the right side of the ventral surface of the sacrum (Figure 11), with associated patches of reactive woven bone on the innominates (hip bones), diffuse porosity of the superior surfaces of clavicae, rib shafts, femoral/tibial shafts, as well as osteomyelitis of the left first metacarpal (base of the thumb). Xray imaging of the destructive lesion (Figure 11) indicates the margins are non-sclerotic (not remodelling), suggesting the possibility the lesion is an aggressive sacral tumour. However, reactive new bone formation on the ilia suggests slow progression. If it is neoplastic in origin, a chordoma is the most common malignant tumour of the sacrum, but a giant cell tumour and chondrosarcoma are also possible causes. The destructive lesions would have caused SK2181 to have lower back pain initially but may have begun to impact the adjacent organs. As the lesion sits towards the right side of the sacrum, the unilateral lesion may have caused hip dysfunction, and possibly bladder issues. Differential diagnoses may include osteomyelitis or tuberculosis.

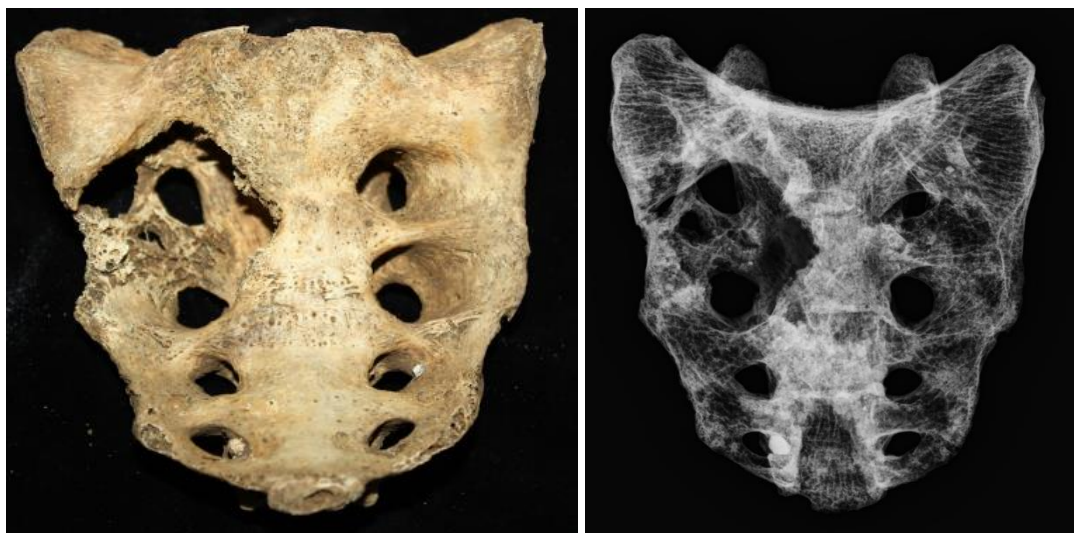

Figure 11: Ventral surface of the sacrum of SK2181 (M, 46+ years). Note the large destructive lesion towards the left of the image.

3.1.5.7.2. Skeleton 2160 (Male, 36-45 years)

From the time of initial discovery, SK2160 was of note. Rather than collapsing in on themselves as they would during the normal decomposition process, the ribs on the right side of the body were in an unusual elevated and

splayed position (Figure 12). Theories began in attempt to explain the unusual rib position, possibly a large, fluid-filled tumour sat within the right side of the chest cavity (for example, an elastofibroma or an aortic aneurysm), which left no trace on the skeleton once the soft tissues decomposed. Osteological analysis identified periosteal reaction on the visceral surface of the ribs on the right side, which would suggest a mass under ribs. Diffuse active new bone was also located on the hands, feet, arms, and bones of the legs suggest secondary hypertrophic osteoarthropathy (Figure 12), which is a common secondary reaction to lung cancer. If this unusual pathology is neoplastic in origin, it is likely the mass was the primary tumour(s), as lesions had not affected adjacent skeletal elements, such as the ribs or vertebrae. The lack of destructive/erosive lesions of ribs or vertebra suggests the tumour was fast growing.

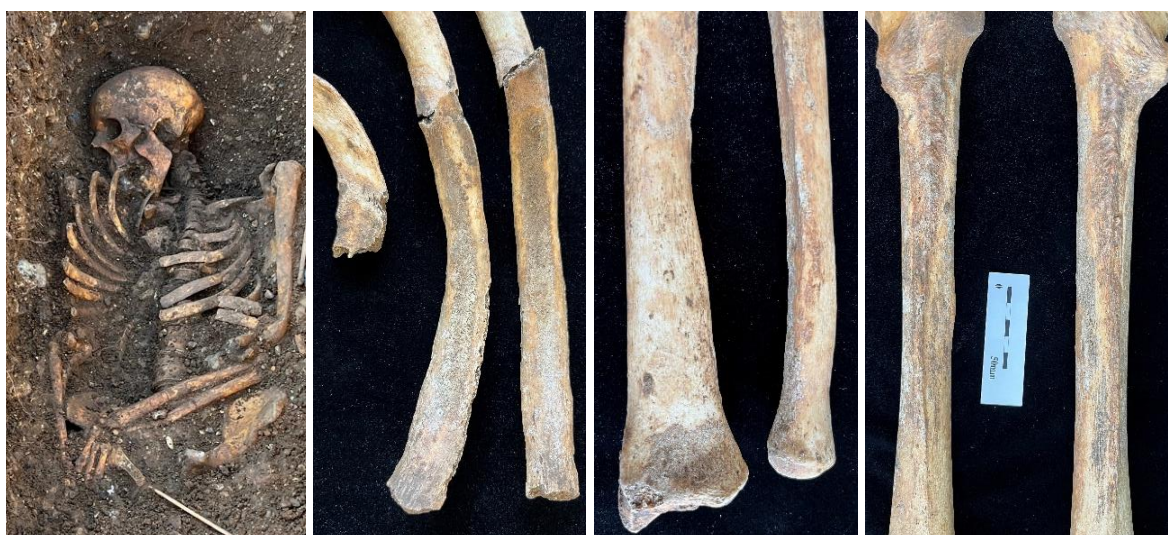

Figure 12: SK2160, excavation (note splayed position of right ribs), and periosteal reaction on right ribs (visceral surfaces), distal right radius and ulna, and posterior femora.

3.1.5.8 Circulatory disease

Disruptions in the circulatory system result in the fragmentation and collapse of skeletal joints. One such pathology is osteochondritis dissecans (OCD), which usually affects young males in the first decade of life (Roberts and Manchester 1995). Bone tissue death occurs following disruption to the area's blood supply, either by normal processes or following chronic traumatic injury. Osteochondritis dissecans is usually 'well-defined, porous, often circular...' (Roberts and Manchester 1995, 89). A total of 6 individuals displayed erosive lesions consistent with OCD (Table 7), all affecting the lower legs and/or feet (CPR = 6/14, 42.9%).

Table 7: Osteochondritis dissecans in the eastern area burials

Skeleton number	Biological Sex	Age (years)	Region	Side	Location of lesion(s)
2160	Male	36-45	Ankle	Right	Inferior talus
2173	Male	36-45	Ankle	Right	Superior calcaneus
2175	Female	36-45	Feet	-	Proximal ends of pedal phalanges
2181	Male	46+	Ankle	Bilateral	Distal tibiae
2182	Female	46+	Base of MT1	Right	Proximal end of first metatarsal
2210	Female	46+	Elbow	Right	Trochlea (posterior/lateral)
			Ankle	Bilateral	Distal tibiae

3.1.5.9 Osteoporosis

In addition to being notably gracile in appearance, the bones of one adult female, SK2210 (46+ years) were light-weight, possibly suggesting the presence of osteoporosis. This condition results from an imbalance in the function of the bone cells, often as a result of the menopause in females (Buikstra et al. 2020). Other contributing factors are sex, diet (i.e., sufficient amounts of calcium and vitamin D inhibit the onset of osteoporosis), circulating sex hormones (e.g., menopause), lack of exercise, and high number of pregnancies, in addition to many other factors (Roberts and Manchester 1995, 177). The decrease in bone mass causes an increased risk of fracture, as the bones become brittle and fragile. Although light-weight skeletal elements may suggest osteoporosis, the crush fractures of the seventh through ninth thoracic vertebral bodies, producing kyphosis towards the right side, support the diagnosis. However, further investigation is strongly recommended.

3.1.5.10 Miscellaneous conditions

3.1.5.10.1 Ischial tuberosities

After the age of 60 years the ageing process has an effect on the topography of the upper ischial tuberosity (i.e., the part of the pelvis that you sit on) (Falys 2013). As age increases, the ischial tuberosity gradually changes from a smooth surface to an irregular one, as nodules of bone form and merge in locations over across the surface. While these changes are not unexpected at Cookham, given the older age of many of the individuals from the eastern area, five individuals (Skeletons 2161, 2171, 2172, 2175, and 2181) had changes not consistent with age. Their tuberosities displayed lytic lesions sometimes in combination with increased rugosity (Figure 13). These erosive lesions may represent pressure sores (decubitus lesions) (Gowland, 2016), produced from being in one position for an extended period of time. More research is needed to investigate these possible lesions further, and their association with individuals with chronic disease and occlusal calculus.

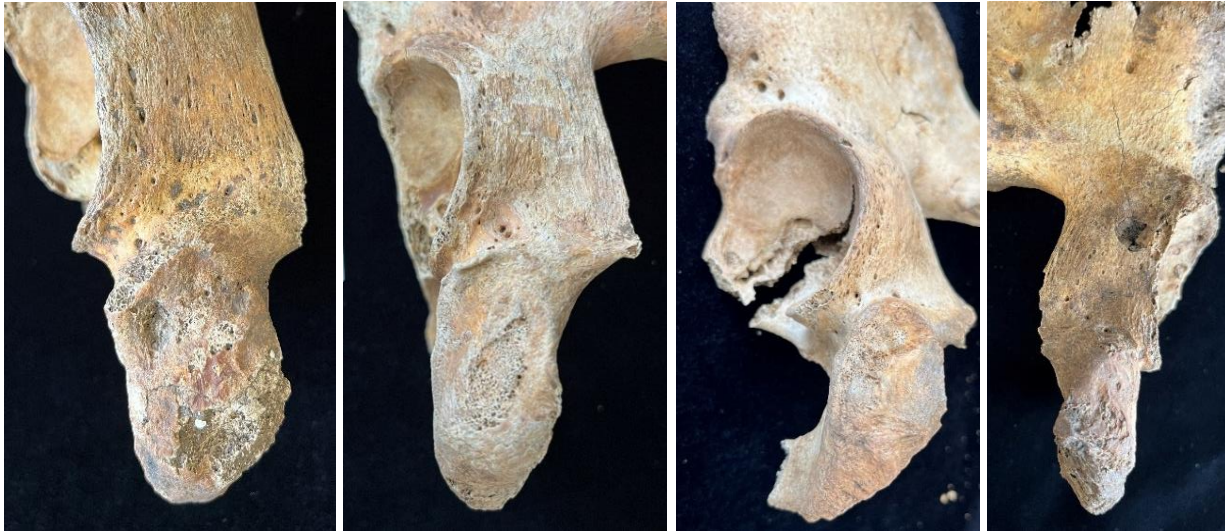

Figure 13: Possible decubitus lesions of the ischial tuberosity (left to right, SK2161 (M, 46+ years), SK2175 (F, 36-45 years), SK2181 (M, 46+ years), SK2210 (F, 46+ years))

3.1.5.10.2 Possible pathologies

Table 8 summarised changes seen on a number of skeletons that warrant further investigation to identify the type of pathology they may have suffered from.

Table 8: Summary of further research needed for the eastern burials

Skeleton number	Biological sex	Age (years)	Description
2160	Male	36-45	Enthesophyte on the medial epicondyle of left femur, accentuated muscle attachments on the inferior/sternal clavicles and proximal humeri.
2168	n/a	10.5-14.5	Blastic lesion on the femur
2169	Male	17-25	Endocranial lesions (lytic) and erosive lesions to left side to T9-T12, L5 body. Abnormal curvature of left radius and ulna (the radial tuberosity is small and more proximal than normal) and fibulae.
2171	Male	46+	Space-occupying lesions on the sella turcica, right superior fossa of occipital bone, and right parietal (arachnoid granulations?), T2 spinous process, ventral ilia.
2173	Male	36-45	Possible erosive lesions on visceral surface of the costal end of a rib, over right orbit (medial), right and left temporal (anterior edge of the squamous/petrous temporal), humeri (proximal), right proximal ulna, large foramina on posterior/anterior ilia with light coloured new bone. odd curvature to left clavicle. Same condition as SK2175?
2175	Female	36-45	Possible erosive lesions on left medial epicondyle (femur), temporal endocranial surfaces, right acetabular rim (superior). all skeletal elements are notably dense and heavy, Same condition as SK2173
2181	Male	46+	nodule on dorsal surface of intermediate manual phalanx
2182	Female	46+	erosive lesions to investigate further (ectocranium, C3 right inferior articular facet, C7 spinous process, proximal femora, superior T12, inferior L1 body), all elements are lightweight (osteoporosis?).
2210	Female	46+	possible neoplastic lesion on cranial vault
2213	Male	46+	possible erosive lesions temporal bones, proximal humeri/femora, L5 neural arch and calcanei
2226	Female	46+	Space occupying lesions to L2 and L3 neural arches?

3.2 Burials from the western side of Trench 2

Nine articulated individuals were excavated from the western end of Trench 2. In contrast to the individual earth-cut graves located towards the eastern side, clear grave cuts were not visible and, although located beneath varying quantities of disarticulated human and animal bone, the burials were shallow and frequently associated with tree roots.

3.2.1 Disarticulated bone

In contrast to the eastern burials, quantities of disarticulated human and animal bone were common in the west, with deposits overlaying the articulated burials. As the excavation proceeded from the upper most deposits, it became apparent that the human bone was not gathered into piles, or pushed out of the way of later burials but rather, some of the bone was being arranged to mark out areas of the western burial ground. This theory will be expanded on in a future skeletal report (COP24).

3.2.2 Preservation and completeness

Likely related to the close proximity of the tree-line, invasive tree roots, and shallow nature of the burials, the overall preservation of the individuals excavated from the western end of Trench 2 was poorer than the eastern side, with a notable increase of fragmentation. The surface preservation was also poorer (Table 9), with most individuals displaying McKinley (2004) Grades 3-5.

3.2.3 Biological sex and age-at-death

Assessments of biological sex and age-at-death for the western burials resulted in a similar demography as discovered in the eastern end. Of the six individuals for whom a biological sex could be estimated there was an equal split of males and females. The three non-adults from this area were of indeterminate sex.

Due to the poorer preservation of the western individuals, fewer areas of the skeleton could be assessed for age. Despite this, adults of a range of ages were identified. The youngest individual was an infant (0-1 years, SK2227) interred on top of the left lower leg of SK2192. The other two children were both aged between 6.5 and 10.5 years (Figure 14, Table 9).

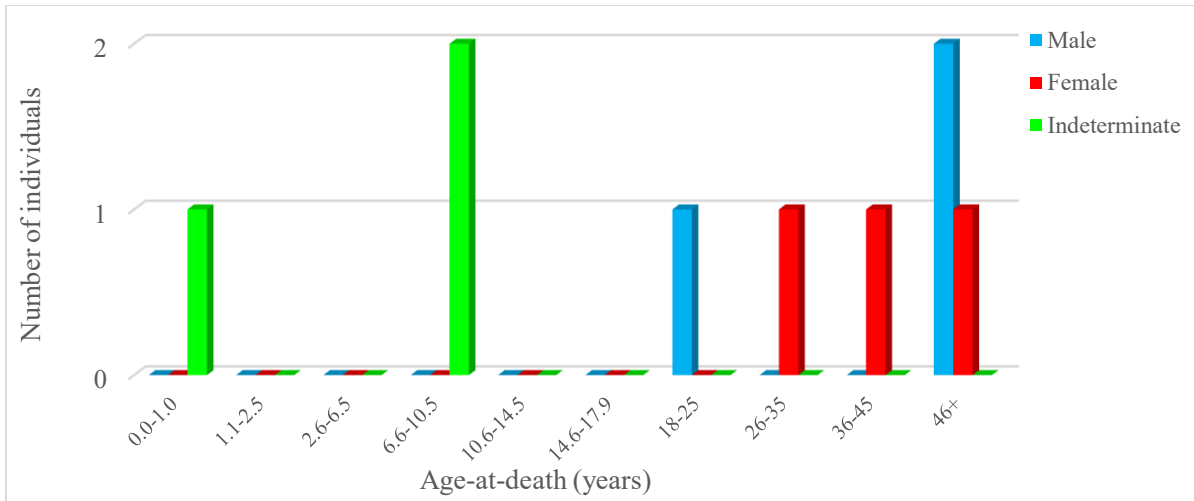


Figure 14: Distribution of biological sex and age-at-death within the western burials

3.2.4 Metrical analysis

Stature was calculated for the three females, with a range of 160.3cm to 160.8cm \pm 3.72cm, with an average of 160.6cm (or 5') (Figure 15). The males had a stature range of 166.1cm to 175.2cm \pm 3.27cm, with an average of 171.5cm (5'7"). Both falling short of the averages reported by Roberts and Cox (2003, 195).

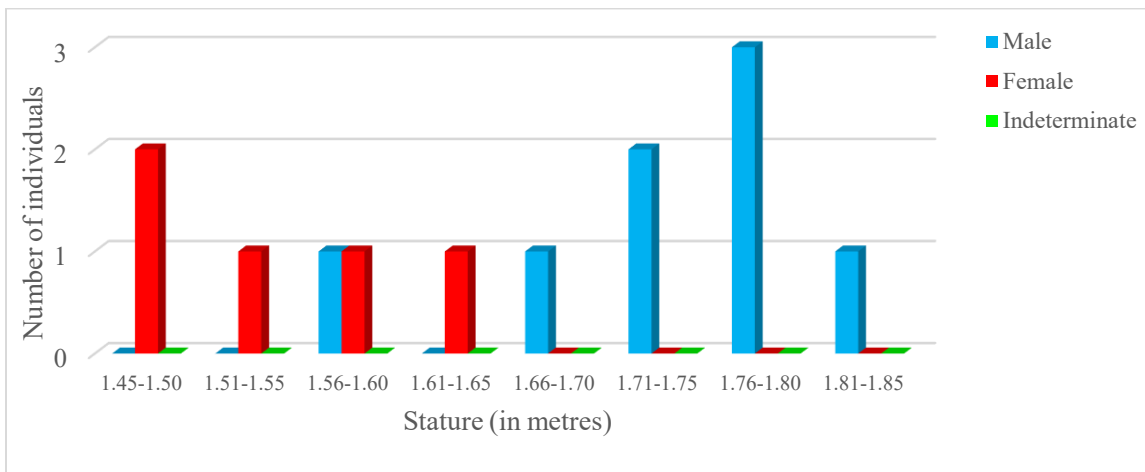


Figure 15: Approximate statures (in metres) for males and females buried towards the western end of Trench 2.

Table 9: Demography and stature of the western burials from Trench 2

Skeleton number	% Complete (surface)	Biological sex	Age (years)	Stature	
				cm	Ft in
2174	50-75 (5)	-	6.5 to 10.5	-	-

Skeleton number	% Complete (surface)	Biological sex	Age (years)	Stature	
				cm	Ft in
2183	75+ (2)	Male	20-25	175.2cm ± 3.27cm (right femur)	5'9"
2184	75+ (4)	Male	46+	166.1cm ± 3.27cm (right femur)	5'5"
2191	50-75 (4)	Female	46+	160.3cm ± 3.72cm (right femur)	5'3"
2192	75+ (2)	Female	26-35	160.8cm ± 3.72cm (right femur)	5'3"
2196	50-75 (3)	Female?	36-45	160.8cm ± 3.72cm (right femur)	5'3"
2200	75+ (3)	Male	46+	173.3cm ± 3.27cm (right femur)	5'8"
2208	25-50 (5)	-	6.5 to 10.5	-	-
2227	<25 (3)	-	0-1	-	-

3.2.5 Skeletal and dental health

The individuals from the western end of trench two were less well-preserved than those from the eastern end, with a higher degree of fragmentation of skeletal elements, especially those of the axial skeletons (i.e., chest, spine, pelvis). It is possible that patterns and prevalence of pathological conditions were masked by the poor preservation. Please see the pathology section for the eastern burials for explanation of identified conditions. The pathological results for the western burials is provided below, and a summary for each individual is provided in Appendix 1.

3.2.5.1. Dental health

Dentition was recovered from seven of the nine western burials, with a total of 143 teeth present for analysis, including 131 adult (permanent) teeth (63 maxillary, 68 mandibular), nine deciduous (baby/milk) teeth (3 maxillary, 6 mandibular), and three unidentified, developing deciduous crowns (SK2227). Overall, the dentition was well preserved, but the mandibulae/maxillae were less so. Despite this, osteological analysis was undertaken to compare the prevalence of antemortem tooth loss, carious lesions (cavities), calculus (plaque deposits), periapical lesions (abscesses), alveolar resorption (gingivitis), linear enamel hypoplasia, with that of the eastern burials. Crude (CPR) and true prevalence rates (TPR) of dental disease are provided where possible, and summaries of dental inventory and disease are provided in Appendix 2.

3.2.5.1.1 Antemortem Tooth Loss (AMTL)

In total, two of the five individuals with observable alveolar processes of the maxilla/mandible (CPR= 2/5, 40.0%; SK2184 (M, 46+ years) and SK2191 (F, 46+ years)), lost four and five teeth, respectively, prior to death. Of the 143 sockets present for analysis, nine displayed antemortem tooth loss (TPR=6.3%).

3.2.5.1.2 Carious Lesions

Excluding the developing deciduous crowns of SK2227, a total of three individuals (CPR = 3/6; 50.0%; SK2183 (M, 17-25), SK2191 (F, 46+ years), and SK2200 (M, 46+ years), displayed between two (SK2191 and SK2200) and four (SK2183) carious lesions (TPR = 8 caries/143 teeth present = 5.6%).

3.2.5.1.3 Calculus

Deposits of calculus were observed on the dentition of five of the six individuals buried in the western aspect of trench 2 (CPR = 5/6, 83.3%). The unaffected individual was SK2174, aged 6.5-10.5 years. The severity of calculus deposits, based on the grading scheme by Brothwell (1981), resulted in four individuals displaying “slight” deposits (SK2183 (M, 17-25 years), 2191 (F, 46+ years), 2192 (F, 26-35 years), and 2200 (M, 46+ years)). The fifth individual, SK2184 (M, 46+ years), had a combination of “medium” calculus deposits on the left side of his dentition, and “considerable” on the right.

Of the five western burials with calculus, two male individuals displayed calculus deposits on the occlusal surfaces of the dentition (most commonly in the wear facets of the molars): SK2183 (17-25 years) and SK2184 (46+ years). The deposits on SK2184 were unilateral, on the right side, although it is noted the left side of the jaw had several teeth lost antemortem. The lack of occlusal calculus on the left side of the mouth, and more severe dental wear suggests SK2184 was able to chew on the left side not the right (Figure 16). Analysis of the right maxilla, mandible and temporomandibular joint did not provide any insights into the reasons why chewing was not taking place on the right side (i.e., absence of lesions that would cause significant pain or paralysis).

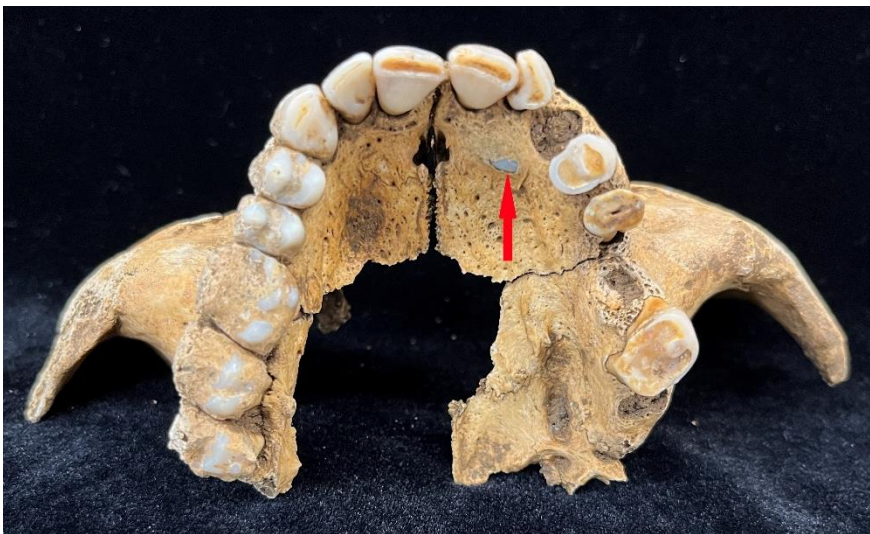

Figure 16: Unilateral maxillary occlusal calculus for SK2184. Also, note impacted tooth crown within the left palate (arrowed).

3.2.5.1.4 Periapical lesions

No periapical lesions were identified within the individuals buried towards the west of Trench 2.

3.2.5.1.5 Periodontal Disease

Half of the individuals buried towards the west of the excavated area had some degree of alveolar resorption (n=3, CPR = 50.0%). The younger individuals, SK2174 (6.5-10.5 years), SK2183 (M, 17-25) and SK2192 (F, 26-35 years) did not display any evidence of periodontal disease. In contrast, SK2184 and SK2200, both males aged 46+ years, had “slight” alveolar resorption, and SK2191 had “considerable” resorption.

3.2.5.1.6 Enamel Hypoplasia

Linear defects of enamel hypoplasia were present on the dentition of five of the six western burials. Only the teeth of SK2191 (F, 46+ years) were unaffected, although it is noted, relative few teeth were recovered for analysis.

3.2.5.2 Congenital and developmental anomalies

Of the eight western burials (excluding infant SK2227), a total of five (5/8, 62.5%) displayed one or more congenital/developmental defect. The condition of spina bifida occulta was observed in two individuals (2/8 individuals, 25.0%), with SK2192 (F, 26-35 years) displaying non-fusion of S3-S5 and SK2196 (F?, 36-45 years) displaying an unfused S1 neural arch. Possibly related to the non-fusion of the first sacral neural arch, SK2196 also had bilateral spondylolysis of the fourth and fifth lumbar vertebral neural arches (non-fusion of the inferior articular facets/spinous process from the rest of the vertebral neural arch).

The spine of one individual, SK2184 (M, 46+ years) had border-shift vertebrae, with the twelfth thoracic vertebra of SK2184 partially lumbarised (the right side has lumbar superior articular facet morphology). The lower back of SK2200 (M, 46+ years) had a supernumerary vertebra, with six lumbar vertebrae instead of the usual five.

A single extra-spinal congenital/developmental defect was observed in the chest of SK2183 (M, 17-25 years), the sternebra of the sternal body (inferior to the manubrium) was unfused in the midline. A sternal foramen was also present.

3.2.5.3 Indicators of non-specific stress

Whether an indication of anaemia, or simply non-specific health stress, the orbits of three individuals within the west of trench 2 (SK2183 (17-25 years), (SK2191 (F, 46+ years), and infant SK2227), displayed cribra orbitalia (pitting of the roof of the eye socket) (CPR = 3/7, 42.9%).

3.2.5.3.1 Long Bone Asymmetry

Maximum long bone lengths of the humeri and/or femora were only possible for five of the western individuals (Table 10 and Figure 17). The most notable asymmetries observed were the femora of SK2196 (the right femur was 0.5cm longer than the left), and SK2183, who is discussed below, with a difference in femora of 1.7cm.

Table 10: Summary of humeral and femoral asymmetry (cm) in the western burials

Skeleton	Biological sex	Age (years)	Humerus			Femur			Stature
			Left	Right	Diff	Left	Right	Diff	
2183	Male	17-25	33.6	33.3	0.3	46.1	47.8	-1.7	175.2cm ± 3.27cm (right femur)
2184	Male	46+	-	30.3	-	44.1	44	0.1	166.1cm ± 3.27cm (right femur)
2192	Female	26-35	-	31.7	-	42.8	43.2	-0.4	160.8cm ± 3.72cm (right femur)
2196	Female?	36-45	-	-	-	42.7	43.2	-0.5	160.8cm ± 3.72cm (right femur)
2200	Male	46+	35.2	35.6	-0.4	-	47	-	173.3cm ± 3.27cm (right femur)

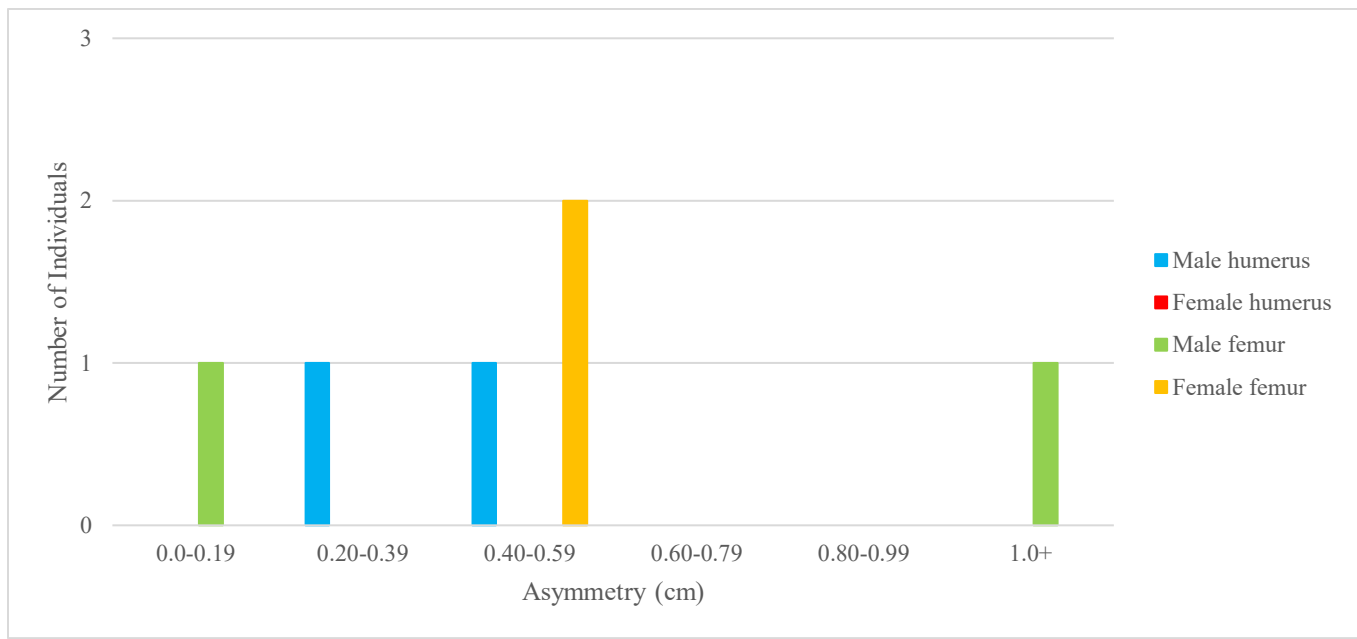


Figure 17: Summary of humeral and femoral asymmetry in the western burials

3.2.5.4 Antemortem Trauma

Two male individuals, both aged 46+ years, had possible well-healed fractures (CPR 22.2%), which require further investigation (Table 11). The first individual (SK2184) appears to have multiple fractures to his clavulae, the left humerus, distal ulnae, left radius, right first metacarpal, fifth metacarpals (bilateral), right tibia and fibula. There are also abnormal depressions or struts on posterior right ilium that might also indicate antemortem trauma. The distal right ulna of the second male (SK2200) requires further investigation to determine whether a well-healed

fracture is present. In addition, the right linea aspera (muscle attachment that runs down the back of the thigh/femur) has extreme muscular development, which might suggest a soft-tissue injury such as myositis traumatica.

Table 11: Summary of antemortem trauma in western burials

Skeleton	Biological sex	Age (years)	Bone(s) affected		Status of healing
			Side	Location(s)	
2184	Male	46+	Left	Clavicle, humerus, radius, ulna, 5 th metacarpal, ilium	Healed
			Right	Clavicle, ulna, 1 st and 5 th metacarpals, ilium tibia, fibula	Healed
2200	Male	46+	Right	Ulna, possible soft tissue injury to right posterior femur	Healed

3.2.5.5 Circulatory disorders

Summarised in Table 12, osteochondritis dissecans, localized erosive lesions caused by the disruption of the blood supply to the bone, were observed in three of the western burials, with a CPR of 37.5% (3/8) (excluding infant SK2227).

Table 12: Circulatory disorders in the western burials: osteochondritis dissecans

Skeleton	Biological Sex	Age (years)	Region	Side	Location of lesion(s)
2183	Male	17-25	Elbow	Right	Distal humerus (anterior trochlea)
			Hip	Left	Femoral head
2184	Male	46+	Feet	Bilateral	First metatarsals and proximal end of pedal phalanx for big toe
2196	Female?	36-45	Feet	Bilateral	Proximal ends of proximal phalanges of big toes

In addition to OCD on the left femoral head, the left hip of SK2183 (M, 17-25 years) was affected by Legg-Calvé-Perthes' disease. This circulatory condition usually appears between the ages of 4 and 8 years, and more commonly in boys than girls (Lewis, 2018, 255). The vascular necrosis of the femoral neck, fragmentation of the femoral head (epiphysis), possible dislocation and subsequent healing results in a deformity of the hip joint. The affected femoral head commonly becomes mushroom-shaped, as observed in SK2183, resulting in a modification of the acetabulum, which was more broad and shallow than the right side to compensate for the flattened and mushroom-shaped femoral head. A marked asymmetry was also noted for the femora (Figure 18), with atrophy of the left femur indicating the left leg was likely not entirely weightbearing or in use to the same extent as the right side. The shortening of the left leg likely limited the mobility of SK2183, however, the cortical defects of the clavicles, ulnae and humeri indicated pronounced musculature of the upper body, supporting the possible use of crutches (or similar equipment) to ease mobility.



Figure 18: Legg-Calvé-Perthes' disease of the left femoral head, with atrophy of the left femur

3.2.5.6 Degenerative Joint Disease (DJD)

Overall, skeletons recovered from the western end of Trench 2 were poorly preserved which limited assessments of pathological change, particularly of the spine. Evidence of degenerative joint disease was observed within the mid-thoracic vertebral bodies of SK2183 (M, 17-25 years), in the form of shallow depressions, characteristic of Schmorl's nodes (CPR = 1/6, 16.7%) (Table 13). Marginal osteophytes (degenerative joint disease) were evident on the vertebrae of two individuals, SK2184 (46+ years) and SK2191 (F, 46+ years). The distal ulnae of SK2184 also displayed DJD.

Table 13: Degenerative joint disease and Schmorl's nodes in adult western burials (n=6)

Joint affected	Males			Females		
	n	Affected	%	n	Affected	%
TMJ	3	-	-	2	-	-
Spine	3	1	33.3	3	1	33.3
Schmorl's nodes	3	1	33.6	3	-	-
Right shoulder	3	-	-	2	-	-
Left shoulder	3	-	-	2	-	-
Right elbow	3	-	-	2	-	-
Left elbow	3	-	-	2	-	-
Right wrist/ hand	3	1	33.3	2	-	-
Left wrist/hand	3	1	33.3	3	-	-
Right hip	3	-	-	3	-	-
Left hip	3	-	-	3	-	-
Right knee	3	-	-	3	-	-
Left knee	3	-	-	3	-	-
Right ankle/foot	3	-	-	3	-	-
Left ankle/foot	3	-	-	3	-	-

3.2.5.7 Non-specific infection

Nine individuals displayed some form of active or well-healed evidence of periosteal reaction (Table 14). The six adults had deposits of woven bone, or areas of porous or striated new bone formation to one or more skeletal elements (CPR = 6/9, 66.7%). All of the children had diffuse light-coloured dense lamellar bone covering many of the fragments present. Additional research is needed to confirm the nature of these deposits (i.e., is it remodelling bone), and their possible aetiology. Overall, the lower limbs (CPR = 9/9, 100%) and cranial vault (CPR = 5/9, 55.6%) most commonly to displayed sub-periosteal new bone.

Table 14: distribution of periosteal reaction (woven bone) in Western burials

SK	Sex	Age	Cranium	Chest	Spine	Pelvis	Upper limb		Lower limb	
							Humerus	Forearm/ hand	Femur	Lower leg/ feet
2174*	n/a	6.5-10.5	Yes	-	-	Yes	Yes	Yes	Yes	-
2183	M	17-25	Yes	-	Yes	-	-	-	Yes	Yes
2184	M	46+	-	-	-	-	-	-	Yes	Yes
2191	F	46+	Yes	-	-	-	-	-	Yes	-
2192	F	26-35	Yes	-	-	-	-	-	Yes?	Yes?
2196	F?	36-45	-	-	-	-	-	-	Yes	Yes
2200	M	46+	-	-	-	-	-	-	Yes	Yes
2208*	n/a	6.5-10.5	-	-	-	-	Yes	-	Yes	Yes
2227*	n/a	0-1	Yes	-	-	Yes	-	-	Yes	-

3.2.5.8 Specific infection

A 46+ years male (SK2200) was the only suspected case of specific infection (TB), based on the presence of erosive, remodelled lamellar bone on endocranial surface of occipital (Figure 19), vertebral erosive lesions (superior T9 and L5), and coronoid fossa of distal humeri. Thick deposits of grey-brown porous woven bone on visceral surface of the ribs and ventral sacrum (S1-S3 bodies) (Figure 19), suggest the condition was ongoing for some time.

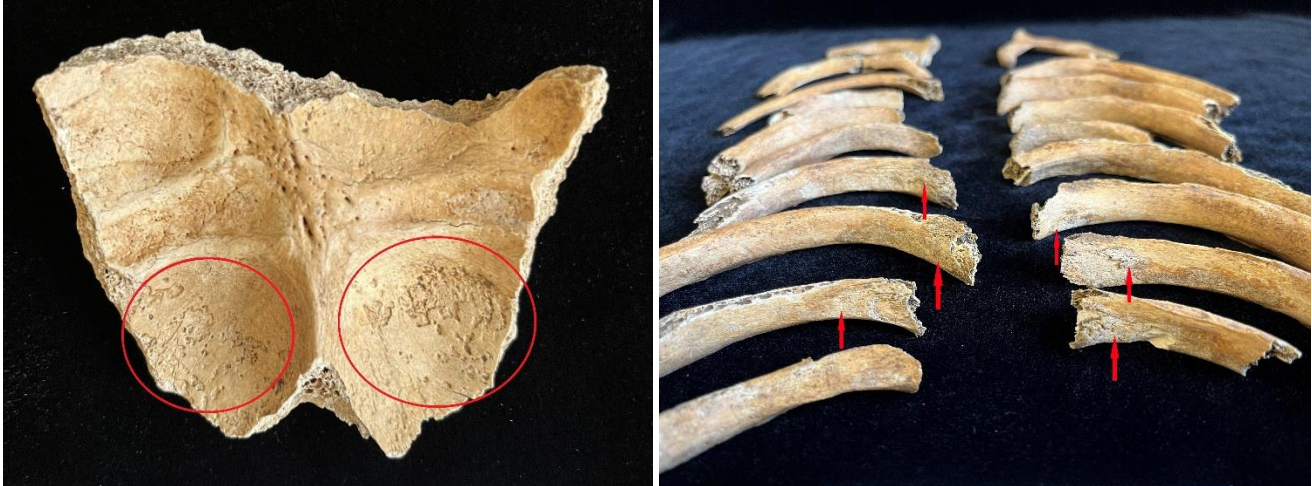

Figure 19: Erosive lesions on the endocranial surface of the occipital bone (circled, left), and woven bone deposits on the visceral surfaces of the ribs (arrowed, right)

3.2.5.9 Neoplastic disease

The cranium of a 26-35 year old female (SK2192) displayed pathological changes to both the ectocranial and endocranial surfaces. The ectocranial surface of the left superior frontal bone displays multiple depressions/ erosive lesions in a localised area near to the coronal suture (Figure 20). The endocranial surface of the left frontal bone has a large, erosive lesion, which is lobulated with a well-defined sclerotic margin when observed on an X-ray (Figure 21). In addition to the lytic nature, a marginal/stellate periosteal reaction is also present. The bony changes are characteristic of a cranial tumour, which make up between 1-4% of all bone tumours. The relatively young age, location, and appearance of the endocranial lesion are most consistent with a meningioma, which tends to affect older individuals, with associated soft tissue expansion. The cause of the lesions on the external surface of the left frontal bone is unclear. It is possible it is a subcutaneous scalp lesion or perhaps an attempt at treatment. SK2192 would have experienced symptoms such as headaches, memory loss, loss of vision and seizures. Additional research is needed to investigate additional possible erosive lesions located on the left knee (patella) and ankle (posterior/lateral left talus).

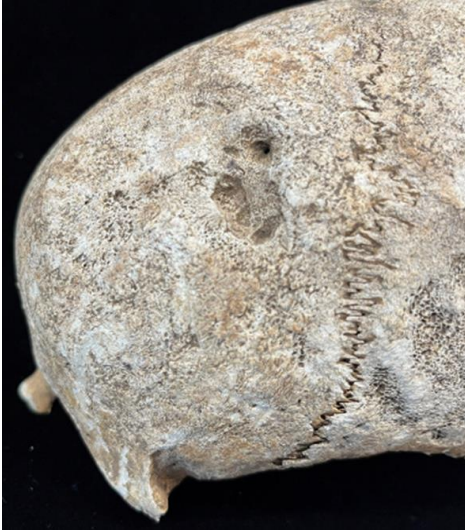

Figure 20: Ectocranial surface of the left frontal bone (SK2192, F, 26-35 years)

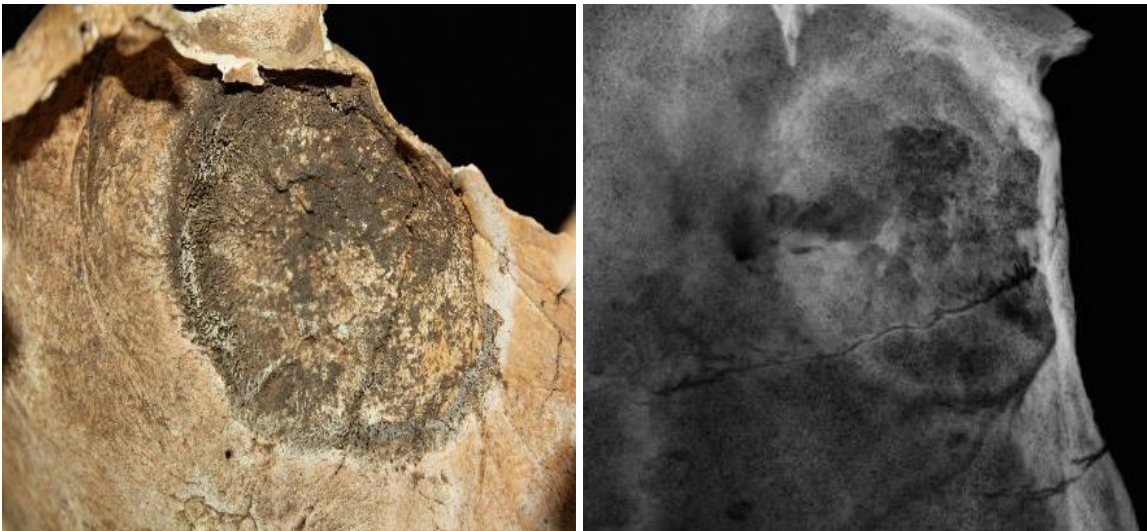


Figure 21: Endocranial surface of the left frontal bone (SK2192, F, 26-35 years), and comparative Xray

3.2.5.10 Further research.

As with the eastern burials, it was not possible to identify the cause or category of pathology of many skeletal observations. Summarised in Table 15, further analyses are needed to investigate the pathological conditions suggested by the identified lesions.

Table 15: Summary of pathological observations (western burials) that require further analysis

Skeleton number	Biological sex	Age (years)	Description
2183	Male	17-25	Anterior angulation of the distal humeri, asymmetric arms, arachnoid granulations
2191	Female	46+	Erosive lesions (?neoplastic): cervical/S1 vertebral bodies and left auricular surface with surrounding spicules of bone. rugged endocranial surface of frontal bone (not classic HFI nodules). Laterally bowed femora, abnormal lateral bowing of the femora (shafts are broad (M-L) and thin (A-P))
2192	Female	26-35	Asymmetric femora, atrophied right humerus. Anterior angulation to distal femora,
2196	Female?	36-45	Irregular morphologies to the lesser trochanters of femora (large and smooth, not small), medial enthesophyte on left lesser trochanter, asymmetrical femora and tibiae
2200	Male	46+	Blastic lesion on proximal/lateral right femoral shaft (Xray needed). asymmetrical humeri, radii and ulnae
2208	-	6.5-10.5	Abnormal femoral shafts (abnormal torsion and thin distal (medial/lateral) distal femoral shafts
2227	-	0-1	Thick deposits of dense, white, porous bone on all elements, possible space-occupying lesion endocranially

3.3. Discussion

Until now, the osteological study of monastic communities has sought to identify the brethren from the lay community, and to better understand their lifestyles and diets. Due to the scarcity of skeletal assemblages from the 7-9th centuries during the establishment of Saxon monasteries, much of this research has focused on the later medieval period. Diet has been investigated through stable isotope analysis and identification of skeletal changes such as DISH, which may suggest many individuals buried at these monasteries ate an excessive and rich diet, and possibly were at risk of obesity and diabetes (Mays 2009). Cookham provides insights into a subsection of the wider early medieval community (or communities) who likely came to the abbey in a time of need.

3.3.1. Demography

During the field seasons of 2022 and 2023, a total of 23 articulated individuals were excavated from the eastern and western areas of Trench 2 (Figure 22). Osteological analysis identified four children among this number, including an infant, who survived birth but did not make it to their first birthday. Two of the children were aged 6.6-10.5 years, and one was a young adolescent, aged 10.6-14.5 years. There was a fairly equal number of adult males (n=10) and females (n=9) and the majority of these were aged over 46+ years (n=10 or 43%).

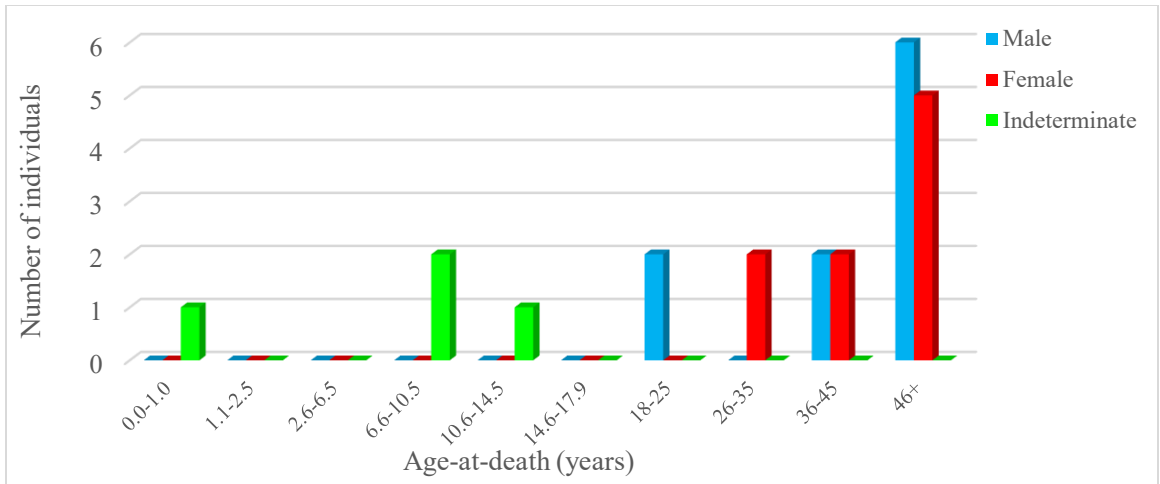


Figure 22: Demography of the combined sample

The cemetery is well organized in a series of rows that run approximately north-south and east-west, with the eastern burials displaying little intercutting (with the exception of burials SK2171 who is cut by SK2172), perhaps suggesting the use of grave markers or other ways to identify where burials have been interred. Analysis of biological sex, age-at-death, and location of burial does not provide any clear patterns, so it is unlikely specific areas were reserved for difference age or gender groups (Figure 23).

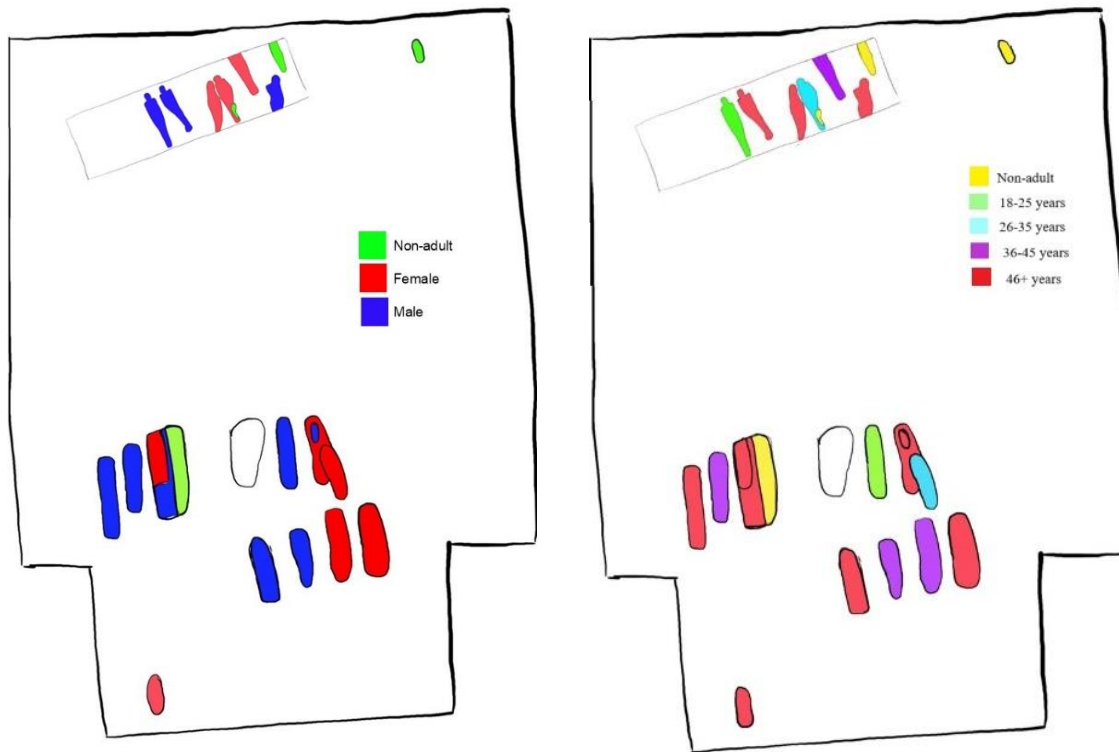


Figure 23: Burial location with respect to biological sex (left), and age-at-death (right)

3.3.2 Stature

Stature was able to be estimated for 18 individuals (10 males and 8 females). Although the number of burials within the western area is relatively small, a comparison of adult stature revealed a 3cm difference in height between males, with those in the east being taller. There was a starker difference between the stature of the females with a 6cm difference, and this time the women to the east were shorter (Table 16). The discrepancy in male heights can be attributed to the presence of two very tall men in the east, SK2169 (181.4cm) and SK2213 (182.3cm). On average, the Cookham males were nearly 2cm taller than the average male stature for the period, reported by Roberts and Cox (2003), and the females were on average 4.3cm shorter (average 161cm, range 152cm-170cm). When compared to the individuals from two contemporaneous cemeteries, the Cookham males were taller than those from Staunch Meadow, but shorter than those buried at Nazingbury. The Cookham females were the shortest of all compared sites.

Table 16: Comparisons of statures (cm) with sites of similar date

Site	Males			Females		
	n	Mean	Range	n	Mean	Range
Cookham (east)	7	174.7	160.2-182.3	5	154.3	150.4-161.1
Cookham (west)	3	171.5	166.1-175.2	3	160.6	160.3-160.8
Cookham (combined)	10	173.8	160.2-182.3	8	156.7	150.4-161.1
Staunch Meadow, Suffolk (Tester et al. 2014)	25	171.8	160.1 (5'3") – 186.5 (6'1")	14	159.9	147.8 (4'10") – 175.2 (5'9")
Nazingbury, Essex	10	175.3	170 (5'7") – 181 (5'11")	13	168.2	158.5 (5'2") – 174.0 (5'8")
Roberts and Cox (2003)	996	172	170-182	751	161	152-170

Although all individuals have a genetic potential to reach a maximum adult stature (i.e., if your parents are tall, then you have the genetic potential to be tall), external factors, such as physical and emotional stressors (e.g., chronic illness, malnutrition, infection, etc.) can limit the genetic potential. The Cookham females are on average, shorter than their peers from other sites of the time and it is possible they experienced chronic poor health, combined with a mixture of other skeletal indicators of non-specific stress (cribra orbitalia, enamel hypoplasia, asymmetric long bones) that affected their growth. Future research could explore the age at menarche in the group (early menarche can affect final stature) and further explore growth and development by analysing vertebral canal size (VNC).

3.3.3 Health Status

By necessity, pathological analysis breaks down observed skeletal anomalies into distinct categories of disease or conditions (e.g., trauma, degenerative joint disease, infection, etc). In some ways, by separating pathology in this way, in order to assess disease expression in the population as a whole, each individual skeleton loses the ability to tell their life story in its entirety. The human body can, and does, experience more than one type of pathology or skeletal anomaly in their remains that either accumulate over time, or occur concurrently. Each individual at

Cookham appears to have experienced multiple events of disease or stress (Appendix 1), and future research should focus on developing an osteobiography for each individual, which provides a powerful way to understand the lived experiences of the people interred at Cookham Abbey.

Looking at the group as a whole, the pathological analysis revealed five separate trends within the health of the Cookham individuals (Appendix 1).

3.3.3.1 Advancing Age

Although a broad range of ages-at-death were present within the excavated graves, nearly half of the individuals were over the age of 46 years. After a lifetime of wear and tear on our bodies and dentition, it is normal for the joints of the skeleton to degenerate (i.e., display osteophytic lipping, porosity), or to develop osteoarthritis after the cartilage between skeletal elements begin to break down (i.e., eburnation). Of the 13 individuals displaying spinal or extra-spinal joint disease, 10 were of advanced age (i.e., 46+ years). The remaining three were 35-45 years (SK2160, SK2173, SK2175). It is also not unusual for dentition to be affected by increasing age in archaeological populations, as the accidental inclusion of grit within food resulting from the food production processes (e.g., using quern stones for grinding flour, etc), increases the severity of dental wear, ultimately predisposing teeth to carious lesions (cavities, CPR 52.6%), the accumulation of calculus from the lack of daily brushing (CPR = 94.7%) and progressive alveolar resorption (periodontal disease/gingivitis, CPR = 68.4%) all promote the loss of permanent teeth (antemortem tooth loss, CPR = 36.8%).

3.3.3.2 Undertaking habitual strenuous activity

In archaeological populations, it is also not unusual to identify skeletal indicators of strenuous activity being undertaken during life. Schmorl's nodes were recorded in nine individuals of both sexes (CPR = 47.4%), which indicate both males and females were undertaking strenuous bending/lifting activities during adolescence while the vertebral bodies were maturing. Other indications of strenuous activity are the erosive lesions (osteochondritis dissecans, OCD), that are formed when the blood supply to an area of bone is disrupted (usually due to localised, repetitive damage/trauma), resulting in localised bone death or necrosis. Overall, 40% of the Cookham adults displayed OCD, with the feet most commonly affected. Also, although a possible underlying genetic predisposition/weakness cannot be discounted, the presence of spondylolysis (non-fusion or fracture of one or more sides of a vertebral neural arch), and os acromiale (incomplete development of the acromial tip of the scapula) can also be considered as indications of strenuous activity from early in life, for example, farming activities.

3.3.3.3 Indicators of non-specific stress

Before the discovery of antibiotics, childhood infections and periods of malnutrition would have been common. These stressors are recorded in skeletal remains in the form of sub-periosteal new bone formation, cribra orbitalia

(iron deficiency) and defects in the forming enamel (hypoplasia). A third of the Cookham individuals ($n = 7/21$, CPR = 33.3%) had cribra orbitalia suggesting possible issues with access to meat and milk during their childhood – or chronic iron deficiency anaemia due to infection. What was unexpected, was the prevalences of enamel defects on the dentition (linear enamel hypoplasia) and non-specific periosteal reaction. A total of 82.6% of the Cookham individuals displayed areas of active or healing periosteal reaction when they died, indicative of physiological stress in the months prior to death. However, skeletal changes also indicate that the individuals experienced periods of stress in their earlier years, with 63.2% of the individuals displaying linear defects of enamel hypoplasia indicating periods of stress (malnutrition, poor health, psychological stress, etc) during childhood while the adult tooth crowns were forming in their jaws (before the age of 7 years). The shortened statures (primarily of the women at Cookham), and observed long bone asymmetries of the bones of the arm (humerus) and leg (femur) may also have resulted from these periods of stress in early years. Future research should further investigate the effect childhood stresses and living conditions had on their bodies through the analysis of vertebral neural canal size and other indicators of non-specific stress.

3.3.3.4 Chronic and debilitating conditions

The most striking aspect of the Cookham individuals that have been excavated so far is the high prevalence of individuals with unusual or severe pathological conditions. Nearly every person suffered some form of health challenge and it is likely that this would have been obvious to those in their community. While previously excavated cemeteries of similar date and context (e.g., Staunch Meadows, Suffolk (Tester et al., 2014) and Nazingbury, Essex (Huggins, 1978)), as well as earlier early medieval sites (i.e., 400-600AD, e.g., Finglesham, Kent (Chadwick Hawkes and Grainger, 2006), Great Chelmsford, Essex (Draper, 1986), and Storey Meadow, West Meon, Hampshire (Ford and Falys, 2016)) report individuals with unusual pathological conditions, who tended to be interred within small clusters within the larger burial grounds. Evidence of similar sites that demonstrate the prevalence and range of disease and physical difference/disability within a larger, densely packed cemetery, such as observed in Cookham, have not been identified during the course of this research. Although, continued excavations of the cemetery area are required to truly understand the burial patterns.

3.3.3.5 Treatment and care

Around 1000CE most ‘medics’ were monks with many ecclesiastical foundations functioning as infirmaries caring for sick monks, nuns and lay people, or ‘those who were about to die’ (Meaney, 2000: 221). Anglo-Saxon medical treatise such as Herbarium of pseudo-Apuleius, the *Medicina de quadrupedibus*, Bald's Leechbook (c.900 CE), and Leechbook III mention several words associated with cancer. The most likely Old English term was ‘bite’ with several of the books providing herbal remedies that would ‘remove the ‘bite’ of the cancer - a word which could mean a general disease (Thompson, 1992). Suggesting perhaps, they sought to relieve the pain of malignancy. There are several records of medics performing surgery on patients with ‘swellings’ in Ely and in Northumbria around

650-700 CE (Meaney, 2000). Several individuals also displayed skeletal changes that suggest they were exceptionally ill leading up to their death (e.g., suffered from a painful tumour or TB). It is possible the abbey housed a medic who was able to provide surgical intervention to hopefully aid the recovery process (i.e., the healing trepanation of SK2171), or perhaps emergency care for those severely injured, such as SK2161, who had extensive perimortem injuries to his head and comminuted fractures throughout body (likely gained through an accident rather than interpersonal violence). Perhaps the abbey could offer objects to aid the lives of people with physical disabilities (e.g., probable crutch-use for the withered leg of SK2168), or provided a home for individuals naturally coming to the ends of their lives (e.g., SK2210 who had extensive degenerative joint disease, rib fractures still in the process of healing, and likely osteoporosis).

If people were coming to Cookham Abbey for medical treatment or hospice care, the skeletons suggest that some may have been cared for over a longer period of time, based on the erosive lesions observed on the ischial tuberosities of the pelves, suggestive of pressure sores, and the presence of patches of calculus deposits on the occlusal surfaces of dentition. Pressure sores suggest individuals were sat/laying down for extended periods of time, during which “bed sores” developed to such an extent that they reached the bone. While occlusal calculus cannot confirm or refute the suggestion that individuals were being physically fed by other people, they do indicate that, for whatever reason, the affected individuals were not able to actively chew food on one or both sides of their mouths for weeks or months leading up to their deaths (either through paralysis or pain), but still they were ingesting food, perhaps some were eating a soft food or liquid diet, as they lived long enough for the plaque deposits to form. Future research should employ the “index of care” (Tilley 2012, 2015; Tilley and Schrenk, 2017), in order to assess which individuals would have required help from others in their communities to live with their health conditions or physical disabilities.

It is acknowledged that it is also a possibility that individuals were not coming, in life, to the abbey for healing, hospice care or hope. Perhaps the cemetery discovered in Cookham is a place where people were to be buried from surrounding communities who were physically distinctive (Hadley 2010), or ‘other’, whether through disease or physical deformity, from the rest of their community – although this is only known from the later periods. In either case, the Cookham individuals provide valuable insights into the health, care, medical treatments, and burial rites available in the early medieval period. Given the high prevalence of rare pathologies, it is strongly likely the individuals buried in this location were from further afield than the local Cookham community. Future research should include stable isotope analysis and aDNA analysis to assess migration within the individuals. The occlusal calculus deposits would have accumulated in the weeks and months leading up to death. If the individuals were being treated with herbal remedies, such as described in the Leech book, chemical analysis of the occlusal calculus deposits would be ideal to identify substances the individuals were ingesting.

3.3.3.6 *Limitations*

Although attempts were made, it was not possible to accurately compare the Cookham findings with those of similar skeletal assemblages, largely due to the broad time periods over which the analysis took place. Osteological and palaeopathological diagnostic criteria have changed greatly over the last 50 years. Future research should also seek to do a wide-scale re-analysis of previously excavated early medieval monastic and non-monastic skeletal collections in order to make osteological and palaeopathological results directly comparable, but using up-to-date osteological standards (e.g., Nazingbury, Finglesham, Staunth Meadow), and test the hypotheses that there were places of healing during the early medieval period (Storey's Meadow, West Meon, Ford and Falys, 2016), or monasteries were actively giving hospice care (Nazingbury, Huggins, 1978). Only then can patterns in the possible medical treatment, health and hospice care, and burial rites be assessed for the early medieval period.

3.4 **Future Research**

The palaeopathological observations from this small portion of the Cookham Abbey cemetery has highlighted the need for extensive future research, which should include:

- 1) Radiographs and further research into the cases of possible antemortem trauma, neoplastic disease, undiagnosed erosive lesions and unusual morphologies of skeletal elements in the COP22/23 individuals.
- 2) Preliminary analysis did not investigate the “index of care” (i.e., needs of the individuals), non-metric traits, or observed unusual dental wear patterns.
- 3) Stable isotope analysis (C/N) to investigate diet, and chemical analysis of calculus deposits with the aim (or possibility) of identifying herbal medicines that may have been used. What insights can be made between the chemical results and writings of Bede? For Anglo-Saxon medicine?
- 4) Stable isotope analysis (Sr/O) to investigate migration, and aDNA for migration studies and to identify possible viruses that may have been present.
- 5) Produce osteobiographies for the individuals to fully understand the life stories their skeletons hold.
- 6) Re-analysis of contemporary early medieval skeletal populations to make data directly comparable in order to assess health, care, treatment, and burial rite in monastic (and non-monastic) communities in early medieval England.

Acknowledgements

Special thanks to the Friends of Cookham Abbey and SAGES (University of Reading) for funding this research, and Mary Lewis (University of Reading) for her analysis and interpretation of the neoplastic disease.

Bibliography

- AlQahtani, SJ, Hector, MP, Liversidge, HM, 2010, Brief Communication: the London atlas of human tooth development and eruption. *Am J Phys Anthropol* 142, 481-490
- Aufderheide, A C and Rodríguez-Martín, C, 1998, *The Cambridge Encyclopedia of Human Paleopathology*, Cambridge
- Barnes, E, 1994, *Developmental Defects of the Axial Skeleton in Paleopathology*, Denver, Colorado
- Berry, A C and Berry, R J, 1967, 'Epigenetic variation in the human cranium'. *Journal of Anatomy*, 101:361-379
- Brickley, M and McKinley, J (eds), 2004, *Guidelines to the Standards for Recording Human Remains*, IFA Paper 7, Reading
- Brooks, S T and Suchey, J M, 1990, 'Skeletal age determination based on the Os Pubis: a comparison of the Acsadi-Nemeskeri and Suchey-Brooks methods', *Human Evolution*, 5, 227-38
- Brothwell, D R, 1981, *Digging up Bones: The Excavation, Treatment and Study of Human Skeletal Remains*, 3rd edn, Oxford
- Buikstra, J E (ed), 2020, *Ortner's Identification of Pathological Conditions in Human Skeletal Remains* (3rd edition), Academic Press, London.
- Buikstra, J E and Ubelaker, D H, 1994, *Standards for Data Collection from Human Skeletal Remains*, Arkansas Archaeological Survey Research Series, 44, Fayetteville, Ark
- Chadwick Hawkes S, Grainger G (2006) *The Anglo-Saxon cemetery at Finglesham, Kent* (ed. B Brugmann). Oxford University School of Archaeology Monograph 64. Oxford: School of Archaeology, University of Oxford.
- Cunha, E and Pinheiro, J, 2009, 'Antemortem trauma', in S Blaus and D H Ubelaker (eds), *Handbook of Forensic Anthropology and Archaeology*, Walnut Creek, Calif, 246-83
- Cunningham, C, Scheuer, L, and Black, S, 2016, *Developmental Juvenile Osteology*, Academic Press, Oxford
- Draper, J, 1986, Excavations at great Chesterford, Essex, 1953-5. *Proceedings of the Cambridge Antiquarian Society*, 75, 3-41.
- Evison, V, 1994, An Anglo-Saxon cemetery at Great Chesterford, Essex. *CBA Research Report 91*.
- Falys, C G, 2013, 'Extending the Life Course: Developing new methods for identifying the "elderly" in the archaeological record', unpubl PhD thesis, Univ Reading
- Falys, C G and Lewis, M E, 2011, 'Proposing a way forward: A review of standardisation in the use of age categories and ageing techniques', *Internat J Osteoarchaeology* 21(6), 704-16
- Falys, C G and Prangle, D, 2015, 'Estimating age of mature adults from the degeneration of the sternal end of the clavicle', *American J Physical Anthropol* 156(2), 203-14
- Falys, C G, Schutkowski, H, Weston, D, 2005, 'The distal humerus--a blind test of Rogers' sexing technique using a documented skeletal collection', *J Forensic Sciences* 50(6), 1289-93

- Finnegan, M, 1978, 'Non-metric variation of the infracranial skeleton', *Journal of Anatomy*, 125:23-37
- Ford, S and Falys C, 2016, *A Bronze Age Ring Ditch and Saxon cemetery at Storey's Meadow, Marland Lane, West Meon, Hampshire*, TVAS Monogr **27**, Reading
- Gowland, R L, 2016, Elder Abuse: Evaluating the Potentials and Problems of Diagnosis in the Archaeological Record, *International Journal of Osteoarchaeology* 26: 514–523
- Hadley, D.M., 2010. Burying the socially and physically distinctive in later Anglo-Saxon England. *Burial in Later Anglo-Saxon England c. 650*, pp.103-115.
- Hillson, S, 1996, *Dental Anthropology*, Cambridge University Press, Cambridge, 108
- Huggins, P J, 1978, Excavation of Belgic and Romano-British Farm with Middle Saxon Cemetery and Churches at Nazeingbury, Essex, 1975-6, *Essex Archaeology and History*, 10:29-117
- Kyere, K, Than, K, Wang, A, et al. 2012, 'Schmorl's nodes', *Eur Spine J* **21**, 2115–21
- Langsjoen, O, 1998, 'Diseases of the dentition', in A C Aufderheide and C Rodriguez-Martin, *The Cambridge Encyclopedia of Human Paleopathology*, Cambridge, 393–412
- Lewis, M E, 2018, *Paleopathology of Children*, London
- Lovejoy, C O, Meindl, R S, Pryzbeck, T R and Mensforth, R P, 1985, 'Chronological metamorphosis of the auricular surface of the ilium: A new method for the determination of adult skeletal age at death', *American J Physical Anthropol* **68**, 15–28
- Mays, S, 2009, The Osteology of Monasticism in Medieval England, in Gowland, Rebecca, and Christopher Knusel, *The Social Archaeology of Funerary Remains*, Oxbow Books, pp. 179-189.
- Meaney, A., 2000. The practice of medicine in England about the year 1000. *Social history of medicine*, 13(2), pp.221-237.
- McKinley, J, 2004, 'Compiling a skeletal inventory: disarticulated and co-mingled remains'. In Brickley, M and McKinley, J (eds), *Guidelines to the Standards for Recording Human Remains*, IFA Paper 7, Reading, p 16
- Mitchell, P. D., & Brickley, M (eds), 2017, *Updated Guidelines to the Standards for Recording Human Remains*. Chartered Institute for Archaeologists/British Association for Biological Anthropology and Osteoarchaeology, Reading.
- Ortner, D J, 2003, *Identification of Pathological Conditions in Human Skeletal Remains* (2nd edn), London
- Resnick, D and Kransdorf, M 2005, *Diagnosis of Bone and Joint Disorders*, 3rd edn, Philadelphia, PA.
- Roberts, C and Cox, M, 2003, *Health and Disease in Britain: From Prehistory to the Present Day*, Stroud
- Roberts, C and Manchester, K, 1995, *The Archaeology of Disease*, (2nd edn), Frome
- Roberts, C and Manchester, K, 2012, *The Archaeology of Disease*, (3rd edn), Stroud

- Roberts, C A, 2009, *Human Remains in Archaeology: A Handbook*, CBA Practical Handbooks in Archaeology, **19**, York
- Rogers, T L, 1999, 'A visual method of determining the sex of skeletal remains using the distal humerus', *J Forensic Sciences* **44**, 57–60
- Schutzkowski, H, 1987, Sex determination of fetal and neonate skeletons by means of discriminate analysis, *Int J Anthropol*, **2**:347-352
- Stewart, TD, 1979, *Essentials of Forensic Anthropology*, Springfield Illinois, C.C. Thomas
- Sutter, R C, 2003, Nonmetric subadult skeletal sexing traits: I. A blind test of the accuracy of eight previously proposed methods using prehistoric known-sex mummies from Northern Chile. *J Forensic Sci*, **48**:927-935
- Tester, A, Anderson, S, Riddler, I and Carr, R, 2014, *Staunch Meadow, Brandon, Suffolk: a high status Middle Saxon settlement on the fen edge*. East Anglian Archaeology Report No. 151
- Tilley, L, 2012, 'The bioarchaeology of care', *The SAA Archaeol Rec* 12:3, 39–41
- Tilley, L, 2015, *The Theory and Practice in the Bioarchaeology of Care*, Cham: Springer
- Tilley, L, and Schrenk, A (eds), 2017, *New Developments in the Bioarchaeology of Care: Further Case Studies and Expanded Theory*, Cham: Springer
- Thompson, P., 1992. The disease that we call cancer. In *Health, disease and healing in medieval culture* (pp. 1-11). London: Palgrave Macmillan UK.
- Trotter, M, 1970, Estimation of stature from intact long bones. In: TD Stewart (ed.) *Personal identification in Mass Disasters* pp. 71-83, Washington DC, Smithsonian Institution Press
- Tyrell, AJ, 2000, Skeletal non-metric traits and the assessment of inter- and intra-population diversity: Past problems and future potential. In Cox, M and Mays, S (eds) *Human Osteology in Archaeology and Forensic Science*. London:Greenwich Medical Media.
- Waldron, T and Rogers, J, 1991, 'Inter-observer variation in the coding osteoarthritis in human skeletal remains', *Internat J Osteoarchaeology* **1**, 49–56
- Walker, P L, Bathurst, R R, Richman, R, Gjerdrum, T and Andrushko, V A, 2009, 'The causes of porotic hyperostosis and cribra orbitalia: A reappraisal of the iron-deficiency-anemia hypothesis', *American J Physical Anthropol* **139**, 109–25
- Weaver, DS, 1980, Sex differences in the ilia of known-sex and age sample of fetal and infant skeletons. *Am J Phys Anthropol*, **52**:191-196

APPENDICES

APPENDIX 1: Summary of the Cookham individuals and the observed pathological conditions

Skeleton	Biological sex	Age (years)	Congenital	Metabolic	Endo	Infection		Joint Disease			Circ	Neop	Trauma		Care?		
						Non Spec	Spec	DJD	OA	SN			Ante	Peri	Occl Calc	Decub	Surg
Eastern burials:																	
2160	Male	36-45		Yes		Yes		Yes		Yes	Yes	Poss	Yes				
2161	Male	46+				Yes		Yes		Yes				Yes			Poss
2168	Male?	10.6-14.5	Yes	Yes			Yes					Poss			Yes		
2169	Male	17-25	Yes			Yes			Yes	Yes			Yes				
2170	Female	46+				Yes			Yes				Yes		Yes		
2171	Male	46+	Yes			Yes		Yes	Yes	Yes		Poss	Yes		Yes	Poss	Yes
2172	Female?	26-35								Yes			Poss				Poss
2173	Male	36-45	Yes			Yes		Yes		Yes	Yes		Yes				
2175	Female	36-45				Yes		Yes			Yes	Poss					Poss
2181	Male	46+	Yes					Yes			Yes	Yes	Yes		Yes	Poss	
2182	Female	46+		Yes	Poss			Yes		Yes	Yes	Poss	Yes				
2210	Female	46+		Yes	Yes	Yes		Yes	Yes		Yes	Poss	Yes				
2213	Male	46+	Yes			Yes		Yes		Yes		Poss			Yes		
2226	Female	46+	Yes					Yes	Yes				Yes				
Western burials:																	
2174	Ind	6.5-10.5		Poss		Yes											
2183	Male	17-25	Yes	Yes		Yes				Yes	Yes				Yes		
2184	Male	46+	Yes					Yes			Yes		Poss		Yes		
2191	Female	46+		Yes		Yes		Yes									
2192	Female	26-35	Yes			Yes						Yes					
2196	Female?	36-45	Yes			Yes					Yes						Poss
2200	Male	46+	Yes			Yes	Yes						Poss				
2208	Ind	6.5-10.5				Yes											
2227	Ind	0-1		Poss		Poss											

APPENDIX 2: Crude prevalence rates of identified pathologies for the eastern and western burials. * = requires further research

Condition	Eastern Burials			Western Burials		
	n	Affected	CPR (%)	n	Affected	CPR (%)
Dental						
AMTL	14	5	35.7 (TPR 13.3)	5	2	40.0 (TPR 6.3)
Caries	13	7	53.9 (TPR 4.7)	6	3	50.0 (TPR 5.6)
Calculus	13	13	100.0	6	5	83.3
Occlusal calculus	13	5	38.5	6	2	33.3
Abscesses	14	4	28.6	6	0	0.0
Periodontal disease	13	10	76.9	6	3	50.0
Enamel hypoplasia	13	7	53.8	6	5	83.3
Congenital / Developmental						
Lumbarisation	12	4	33.3	6	1	16.7
Spina bifida occulta	13	5	38.5	6	2	33.3
Spondylolysis	12	1	8.3	6	1	16.7
Os acromiale	13	1	7.7	6	0	0.0
Trauma						
Antemortem	14	*9	64.3*	9	2	22.2
Perimortem	14	1	7.1	9	0	0.0
Joint Disease						
DJD	13	10	76.9	6	3	50.0
OA	14	4	28.6	6	0	0.0
Schmorl's nodes	13	8	61.5	6	1	16.7
Non-specific infection						
Sub-periosteal new bone	14	10	71.4	9	9*	88.9
Sinusitis	8	1	12.5	4	0	0.0
Specific infection	14	1	7.1	9	1	11.1
Circulatory	14	6	42.9	8	3	37.5
Metabolic						
Cribriform orbitalia	14	4	28.6	7	3	42.9
Neoplastic	14	*2	14.3	9	*1	11.1

APPENDIX 3: Crude prevalence rates of identified pathologies for the combined Cookham sample (east and west burials together), compared with the findings of Roberts and Cox (2003).

Condition	Combined Cookham Sample			Roberts and Cox (2003)	Staunch Meadow, Brandon (Tester et al. 2014)
	n	Affected	CPR (%)	CPR (%)	CPR (%)
Dental					
AMTL	19	7	36.8 (TPR 11.6)	3.1 (TPR 8.0)	
Caries	19	10	52.6 (TPR 4.2)	5.2 (TPR 4.2)	TPR 1.0
Calculus	19	18	94.7	39.2	54.0
Occlusal calculus	19	7	36.8	-	
Abscesses	20	4	20.0	3.9	TPR 2.5
Periodontal disease	19	13	68.4	10.1	16.1
Enamel hypoplasia	19	12	63.2	8.9 (TPR 7.4)	
Congenital/ Developmental					
Lumbarisation	18	5	27.8	0.5	
Spina bifida occulta	19	7	36.8	1.3	0.6
Spondylolysis	18	2	11.1	1.3	
Os acromiale	19	1	5.3	0.4	
Trauma					
Antemortem	23	11*	47.8		
Perimortem	23	1	4.3		
Joint Disease					
DJD	19	13	68.4		
OA	20	4	20.0	8.8	
Schmorl's nodes	19	9	47.4	2.9	11.4
Non-specific infection					
Sub-periosteal new bone	23	19	82.6		
Sinusitis	12	1	8.3	1.3	
Specific infection	23	2	8.7	6.5	
Circulatory	22	9	40.9	-	
Metabolic					
Cribra orbitalia	21	7	33.3	5.7	
Neoplastic	23	3*	13.0	-	

Note, prevalence rates by Roberts and Cox (2003) are lower than the comparative sites due to a much larger sample size.

APPENDIX 4: Skeleton Catalogue (in separate PDF)